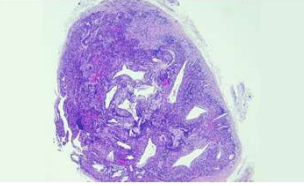
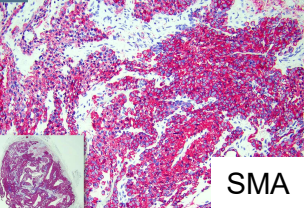


日期	時間	活動	Case of the week
12/4 週一			
12/5 週二	08:00-08:30	※ 臨床病例討論會 R1 侯秉宸 (3F門診討論室) 【全科人員】 1. Approach to cutaneous hypomelanosis in children / VS 李玉雲 2. Necrotizing fasciitis presenting with prominent purpura and hemorrhagic bullae / VS 杜威廷	41-year-old male with a tender papule over subungual area of right 5th fingernail with nail dystrophy for 3 years.
	08:30-09:00	※ 出院病例討論會 R1 張藝瀚 (3F門診討論室) 【全科人員】	
12/6 週三	08:00-09:00	※ 住診教學 / VS 何英右 (11B討論室) 【Clerks, PGYs, Rs】	
	13:00-15:00	※ 臨床病理討論會 (括弧內為討論重點) R2 賴奕慈 / VS 李玉雲 (3F門診討論室) 【全科人員】	
		1. Skin, index finger, left; excision: Acquired digital fibrokeratoma. (The clinicopathology review and differential diagnosis of acquired digital fibrokeratoma.) / R4 林謙	
		2. Skin, arm, left, biopsy: Subcorneal vesiculopustular dermatitis, consistent with AGEP (acute generalized exanthematous pustulosis).(The clinicopathology review of AGEP vs. pustular psoriasis.) / VS 杜威廷	
		3. Skin, upper chest, right; biopsy: Fungal infection with subtle granulomatous dermatitis.(The clinicopathology review of cryptococcosis.) / VS 何英右	
		4. Skin, leg, left; biopsy: Suggestive of lipodermatosclerosis (an early lesion).(The clinicopathology review of lipodermatosclerosis.) / R4 林謙	
5. Skin, scalp, left; biopsy: Perivascular dermatitis without mucin deposition or basement membrane zone thickening.(The clinicopathology review of lipedematous of scalp.) / VS 杜威廷			
6. Skin, frontal scalp; excision: Folliculosebaceous cystic lesion.(The clinicopathology review and differential diagnosis of sebaceous trichofolliculoma and folliculosebaceous cystic hamartoma.) / VS 朱家葆			
12/7 週四	08:00-08:30	※ 專師衛教：頭髮相關衛教單張 NP 高鳳吟 / VS 楊朝鈞 (3F門診討論室) 【全科人員】	
	08:30-09:00	※ 皮膚外科期刊討論會 R4 黃信奮 / VS 何英右 (3F門診討論室) 【全科人員】 Anticipated Versus Unanticipated Incomplete Mohs Micrographic Surgery for Keratinocyte Carcinomas: Impact on Treatment Delays and Final Margin Status. <i>Dermatol Surg.</i> 2023 Dec 1;49(12):1066-1071.	
12/8 週五	08:00-09:00	※ 住院醫師讀書會: Fitzpatrick 9e Ch. 22-23 R2 賴奕慈 (3F門診討論室) 【住院醫師】	
12/9 週六		※ 值班主治醫師查房	
12/10 週日		※ 臺灣皮膚科醫學會第49屆年會 (高雄展覽館)	Answer for last week: Molluscum contagiosum