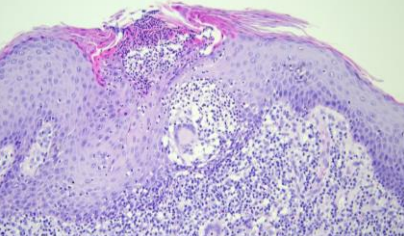
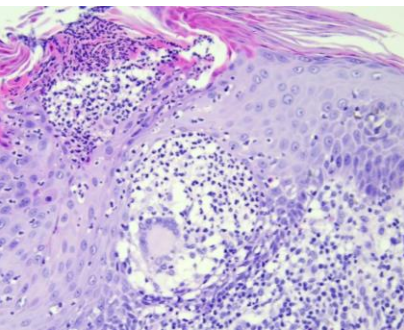
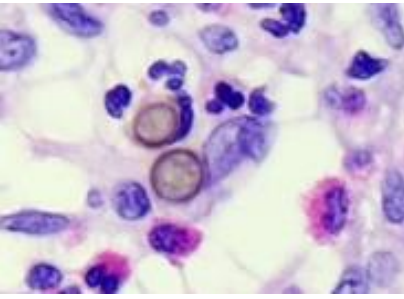


日期	時間	活動	Case of the week
12/25 週一			
12/26 週二	08:00-09:00	※ 研究專題討論會 / VS 許釗凱 (3F門診討論室) 【全科人員】 1. The Evolving Molecular Science of Keloids. VS 許釗凱 2. Review pathology-proven lipodystrophy in NCKUH & Introduction of lipodystrophy R3 葉芮苙 centrifugalis abdominalis infantilis 3. 日本京都大學皮膚科見聞分享 R3 葉芮苙	57-year-old male with one asymptomatic erythematous hyperkeratotic plaque on left thigh for 6 months.
12/27 週三	08:00-09:00	※ 住診教學 / VS 何英右 (11B討論室) 【Clerks, PGYs, Rs】	  
	13:00-15:00	※ 臨床病理討論會 (括弧內為討論重點) R2 曾怡倫 / VS 李玉雲 (3F門診討論室) 【全科人員】	
		1. Soft tissue, face, left; excision: Granulomatous inflammation, compatible with sarcoidosis. (clinicopathological review of sarcoidosis) / VS 趙曉秋	
		2. Skin, bigtoe, right; shave biopsy: Verruca vulgaris. (clinicopathological review of Verrucous carcinoma of nail unit vs verrucus vulgaris) / VS 趙曉秋	
		3. Skin, arm, right; biopsy: Consistent with acute generalized exanthematous pustulosis (AGEP). (clinicopathological review of acute generalized exanthematous pustulosis (AGEP)) / VS 趙曉秋	
		4. Skin, cheek, right, excision: Papillomatosis with epidermal hyperplasia. (clinicopathological review of stucco keratosis) / VS 廖怡貞	
5. Skin, right face, excision: Arteriovenous hemangioma. (clinicopathological review of arteriovenous hemangioma (cirroid aneurysm)) / VS 趙曉秋			
6. Skin, flank, right; biopsy: Compatible with psoriasis. (clinicopathological review of cancer drug therapy related psoriasis and treatment suggestion) / VS 朱家葆			
12/28 週四		※ 全院GPC因故延期至2024/1/10(三) (醫學院第四講堂) 【全科人員】	
12/29 週五	08:00-09:00	※ 住院醫師讀書會: Fitzpatrick 9e Ch. 22-23 R2 賴奕慈 (3F門診討論室) 【住院醫師】	
12/30 週六		※ 值班主治醫師查房	
12/31 週日			Answer for last week: Verruciform xanthoma