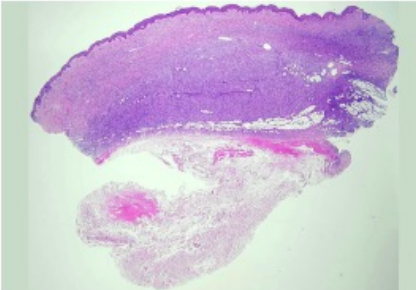
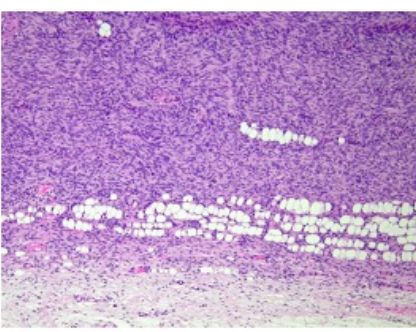
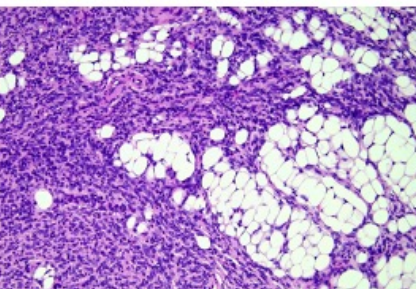


週	日期	時間	活動	Case of the week	
一	1月22日			This is a 42-year-old male without any underlying disease. He was referred to our OPD with progressive multiple papuloplaques with violaceous change and skin atrophy at right clavical area for 18 years	
二	1月23日	08:00-08:30	※ 臨床病例討論會 R1 侯秉宸 (3F門診討論室) 【全科人員】 Epidermolysis bullosa pruriginosa with concomitant lichen amyloidosis /VS 許釗凱 Premature graying of the hair: What are the potential causes ? /VS 楊朝鈞		
		08:30-09:00	※ 出院病例討論會 R1 張藝瀚 (3F門診討論室) 【全科人員】		
三	1月24日	08:00-09:00	※ 住院醫師讀書會: Fitzpatrick 9e Ch. 40 R3 王瀚棠 (3F門診討論室) 【Rs】		
		13:00-15:00	※ 臨床病理討論會 (括弧內為討論重點) R2 賴奕慈 /VS 李玉雲 (3F門診討論室) 【全科人員】 1. Skin, sole, right; biopsy: Keloidal scar. (The clinicopathology review and differential diagnosis of plantar keloid and plantar fibromatosis) /VS 許釗凱 2. Abdomen, biopsy: Subcutaneous panniculitis-like T-cell lymphoma. (The clinicopathology review of subcutaneous panniculitis-like T-cell lymphoma (SPTCL)) /VS 杜威廷 3. Skin, glans penis; biopsy with direct immunofluorescence: Interface dermatitis, compatible with lichen planus. (The clinicopathology review and differential diagnosis of penile lichen planus) /VS 楊朝鈞 4. Skin, neck, biopsy: Compatible with scleredema. (The clinicopathology review of scleredema) /VS 楊朝鈞 5. Skin, arm, left; biopsy: Lichen amyloidosis. (The clinicopathology review of lichen amyloidosis) /VS 楊朝鈞 6. Skin, forearm, left; excision: Vascular malformation, arteriovenous type. (The clinicopathology review of cirroid aneurysm) /VS 何英右		
四	1月25日	08:00-08:30	※ PGY seminar PGY 陳冠瑜 (3F門診討論室) 【全科人員】 Foreign Body Granulomas after the Use of Dermal Fillers: Cases in NCKUH /VS朱家葆		
		16:00-17:00	※ 皮膚整外聯合討論會 (住院大樓2F病理科會議室) 【全科人員】		
五	1月26日	08:00-09:00	※ 住診教學 VS 楊朝鈞 (11B討論室) 【Clerks, PGYs, Rs】		
六	1月27日		※ 值班主治醫師查房		
日	1月28日		※ Answers of the last week's case: prokeratosis		

CD34: diffusely strong positive
Factor XIII a: negative