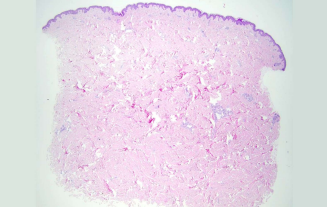
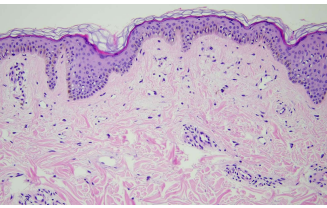
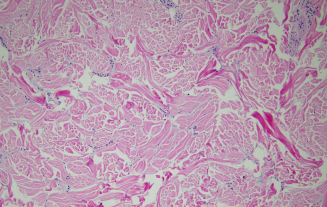
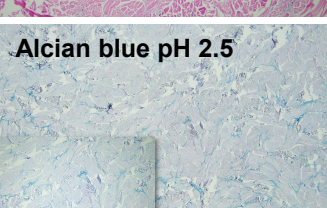
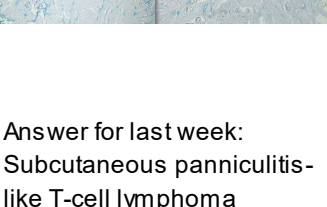



日期	時間	活動	Case of the week	
2/5 週一			57-year-old male with diabetes reported an asymptomatic indurated plaque on posterior neck for years.	
2/6 週二	08:00-09:00	※ 研究專題討論會 / VS 廖怡貞 & 許釗凱 (3F門診討論室) 【全科人員】 1. From Clinics to Transcriptomes: Hailey-Hailey Disease Before and After Low Dose Naltrexone R4 黃信奮 2. Hailey-Hailey disease VS 廖怡貞		
2/7 週三	08:00-09:00	※ 住診教學 / VS 許釗凱 (11B討論室) 【Clerks, PGYs, Rs】 ※ 臨床病理討論會 (括弧內為討論重點) R2 曾怡倫 / VS 李玉雲 (3F門診討論室) 【全科人員】	     	
	13:00-15:00	1. Skin, palm, left; biopsy: Compatible with palmoplantar keratosis (The clinicopathological review of epidermolytic palmoplantar keratoderma) / VS 趙曉秋 2. Skin, left cheek, biopsy: Spongiotic dermatitis with parakeratosis and acantholysis. (The clinicopathological review of isolated pemphigus) / VS 趙曉秋 3. Skin, lower lip, biopsy: Ulcer with dense lymphocytic infiltration. (The clinicopathological review of oral discoid lupus erythematosus and pseudolymphomatous Infiltrate) / VS 趙曉秋 4. Soft tissue, anterior chest, left; biopsy: Dermatofibrosarcoma protuberans. (The clinicopathological review of Dermatofibrosarcoma protuberans) / VS 廖怡貞 5. Skin, flank, left, biopsy: Spongiotic psoriasiform dermatitis, favor guttate parapsoriasis (The clinicopathological review of parapsoriasis) / VS 趙曉秋 6. Skin and soft tissue, forearm, right; excision: Mucinosis. (The clinicopathological review of Solitary cutaneous focal mucinosis) / VS 朱家葆		
				Alcian blue pH 2.5
	08:00-08:30	※ 臨床案例討論會 R1 張藝瀚 (3F門診討論室) 【全科人員】 1. Oral and genital ulcers: suspect Behcet's disease / VS 廖怡貞 2. Differential diagnosis of soft tissue tumor of foot: plantar fibromatosis / VS 許明隆		
	08:30-09:00	※ 出院案例討論會 R1 侯秉宸 (3F門診討論室) 【全科人員】		
2/9 週五			Answer for last week: Subcutaneous panniculitis-like T-cell lymphoma	
2/10 週六		※ 農曆春節連假值班主治醫師查房		
2/11 週日				