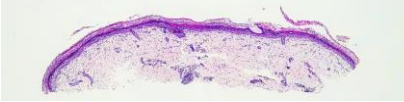
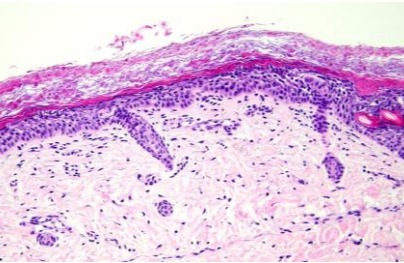
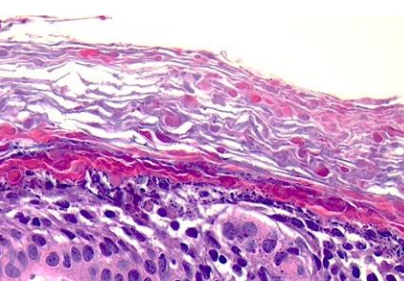
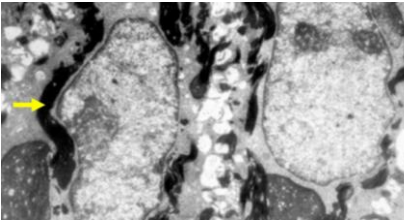


日期	時間	活動	Case of the week
4/1 週一	12:00-13:00	※ 皮膚癌症團隊會議 (3F門診討論室)	A newborn with multiple flaccid bullae leaving erosions and diffuse erythematous scales over the whole body.
4/2 週二	08:00-08:30	※ 臨床案例討論會 1. Differential diagnosis of oral white lesions 2. Risk of skin malignancy in porokeratosis R1 侯秉宸 (3F門診討論室) 【全科人員】 /VS 劉威廷 /VS 李玉雲	
	08:30-09:00	※ 出院案例討論會 R1 張藝瀚 (3F門診討論室) 【全科人員】	
4/3 週三	08:00-09:00	※ 住診教學 /VS 廖怡貞 (11B討論室) 【Clerks, PGYs, Rs】	
	13:00-15:00	※ 臨床病理討論會 (括弧內為討論重點) R2 曾怡倫 / VS 李玉雲 (3F門診討論室) 【全科人員】	
		1. Skin, foot, right, biopsy: Neutrophil-rich arteritis (Clinicopathology review and differential diagnosis of small vessel vasculitis) /VS 劉威廷	
		2. Skin, right nasolabial fold; biopsy: Mantle cell hyperplasia (Clinicopathology review of Cutaneous B cell pseudolymphoma) /VS 楊朝鈞	
15:30-16:30	3. Skin, face, right, biopsy: Spongiosis dermatitis with superficial fungus infection. (Clinicopathology review of steroid rosacea) /VS 李玉雲		
	4. Vulva, right; biopsy: Mild epidermal hyperplasia with dermal fibrosis (Clinicopathology review of lichen sclerosus et atrophicus) /VS 楊朝鈞		
4/4 週四		5. Skin, knee, left, excision: Hemangioma. (Clinicopathology review of vascular malformation, capillary type, mixed with capillary hemangioma) /VS 趙曉秋	
		6. Skin, right leg, biopsy: Subepidermal vesicle with lichenoid lymphoplasmacytic infiltration (Clinicopathology review of Pemphigoid nodularis) /VS 王德華	
4/5 週五		※ 特別演講 林口長庚皮膚部 鐘文宏教授 (3F門診討論室)	KRT1 heterozygous mutation +
4/6 週六		嚴重藥物不良反應的轉譯醫學研究	
4/7 週日		※ 值班主治醫師查房	