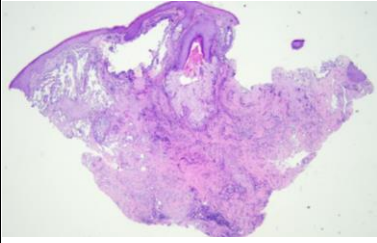
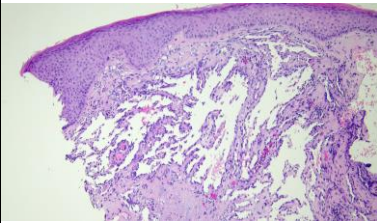
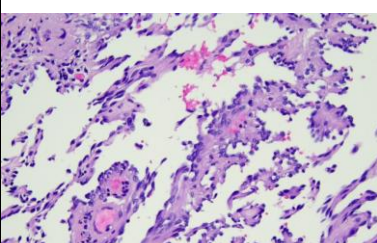
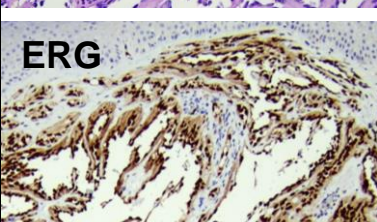



日期	時間	活動	Case of the week	
4/15 週一				
4/16 週二	08:00-09:00	<p>※ <b>醫學期刊討論會</b> / VS 杜威廷 (3F門診討論室) 【全科人員】</p> <p>1. Improvements in pincer nail deformity occur earlier and last longer when acetylcysteine gel is added to an overcurvature-correcting device: Results of a phase 3, multicenter, randomized, vehicle-controlled, investigator-blinded study. <i>The Journal of Dermatology</i>. 2024;51(1):23-9. R3 王瀚棠</p> <p>2. Variants in the Gene Encoding Filaggrin Cause Autosomal-Dominant Symmetrical Acral Keratoderma. <i>The Journal of Investigative Dermatology</i>. 2023;143(7):1313-7.e8. R3 葉芮苙</p>	80y male with an erythematous infiltrative multinodular plaque on central face for 1 year.	
4/17 週三	08:00-09:00	<p>※ <b>住診教學</b> / VS 廖怡貞 (3F門診討論室) 【Clerks, PGYs, Rs】</p>	    <b>ERG</b> 	
	13:00-15:00	<p>※ <b>臨床病理討論會</b> (括弧內為討論重點) R2 曾怡倫 / VS 李玉雲 (3F門診討論室) 【全科人員】</p> <p>1. Skin, knee, right; excision: Spitz nevus. (The clinicopathology review of Spitz nevus vs spitzoid tumor (BAPoma)) / VS 許釗凱</p> <p>2. Skin, finger, 4th, dorsum, left; biopsy: Papillomatous epidermal hyperplasia. (The clinicopathology review of acral acanthosis nigricans) / R4 林 謙</p> <p>3. Skin, abdomen, right, biopsy: Eosinophilic cellulitis-like dermatitis (The clinicopathology review of eosinophilic cellulitis) / R4 林 謙</p> <p>4. Skin, hand, right, biopsy: Compatible with acquired idiopathic anhidrosis (The clinicopathology review of acquired idiopathic anhidrosis) / VS 許釗凱</p> <p>5. Skin, buttock, left, biopsy: Thick horny layer with psoriasiform epidermal hyperplasia and multiple conoid lamellae. (The clinicopathology review of porokeratosis ptychotropica ) / 奇美醫院</p> <p>6. Skin, face, right, biopsy: Several subcorneal pustules with overlying epidermal excoriated necrosis (The clinicopathology review of factitial dermatitis) / 奇美醫院</p>		
		15:00-16:00		<p>※ <b>產品資訊：安適康Anscare</b> 明基材料 (3F門診討論室)</p>
		08:00-09:00		<p>※ <b>外訓醫師討論會</b> (3F門診討論室) 【全科人員】</p> <p>1. Ultrahigh frequency transcutaneous electrical nerve stimulation for neuropathic pain alleviation and neuromodulation PGY2 林昱文 / VS 廖怡貞</p> <p>2. Cutaneous manifestations of diabetes mellitus 慈濟家醫R2 張詩琳 / VS 何英右</p> <p>3. Therapy update of androgenetic alopecia 家醫R4 蔡秉均 / VS 杜威廷</p>
4/18 週四				
4/19 週五	08:00-09:00	<p>※ <b>住院醫師讀書會</b>: Fitzpatrick 9e Ch. 61, 68 R4 林 謙 (3F門診討論室) 【住院醫師】</p>		
4/20 週六		<p>※ <b>值班主治醫師查房</b></p>	<p>Answer for last week: Necrolytic migratory erythema or deficiency dermatitis</p>	
4/21 週日				