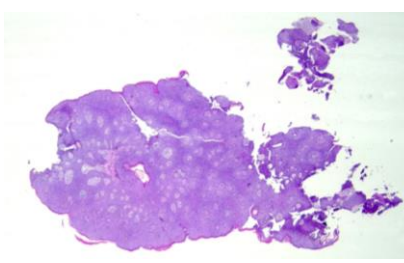
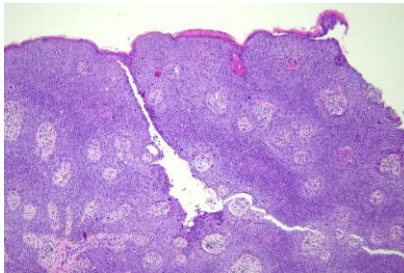
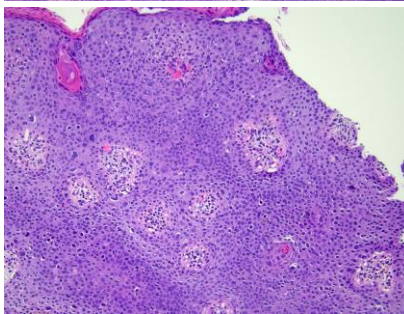
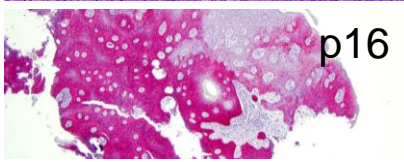
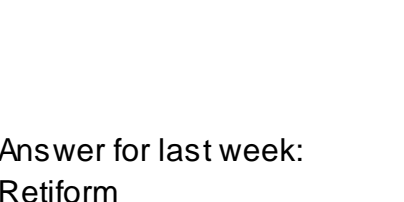


日期	時間	活動	Case of the week
4/22 週一			
4/23 週二	08:00-08:30 院長室訪查	※ 研究專題討論會 Response to erlotinib treatment in epidermolytic palmoplantar keratoderma VS 杜威廷 (3F門診討論室) 【全科人員】	65y male with a pigmented exophytic papule on genitalia for 3 months. 
	08:30-09:00	※ 臨床案例討論會 1. Review of the management of retiform hemangioendothelioma / VS 李玉雲 2. The tunneling technique of intralesional 5-FU in combination with KA injection for keloids / VS 許釗凱	
4/24 週三	08:00-09:00	※ 住診教學 / VS 廖怡貞 (3F門診討論室) 【Clerks, PGYs, Rs】	   
	13:00-15:00	※ 臨床病理討論會 (括弧內為討論重點) R2 曾怡倫 / VS 李玉雲 (3F門診討論室) 【全科人員】 1. Skin, flank, right, biopsy: Spongiotic dermatitis with atypical lymphocytic infiltrate. (The clinicopathology review of hypopigmented mycosis fungoides) / VS 楊朝鈞 2. Skin, face, right; biopsy: Granulomatous dermatitis (The clinicopathology review of leprosy) / VS 朱家葆 3. Skin, subcutis, temporal scalp, right, excision: Mesothelioma, metastatic. (The clinicopathology review of Mesothelioma) / VS 廖怡貞 4. Skin, lower eyelid, right, excision: Compatible with connective tissue nevus. (The clinicopathology review of nevus anelasticus) / VS 趙曉秋 5. Skin, thigh, right; biopsy: Epidermal necrosis with features of vasculitis. (The clinicopathology review of Degos disease) / VS 廖怡貞 6. Skin, auricular, right, excision: Capillary hemangioma. (The clinicopathology review of infantile hemangioma vs pyogenic granuloma vs cherry angioma and tufted angioma) / R4 林謙	
4/25 週四	08:00-09:00	※ 特別演講 Prof. Georgios Kokolakis (第四講堂) 【全科人員】 Treatment of Psoriasis Arthritis: from the view of dermatologist	
4/26 週五	08:00-09:00	※ 住院醫師讀書會: Fitzpatrick 9e Ch. 62,67,69 R1 侯秉宸 (3F門診討論室) 【住院醫師】	
4/27 週六		※ 值班主治醫師查房	Answer for last week: Retiform hemangioendothelioma
4/28 週日			