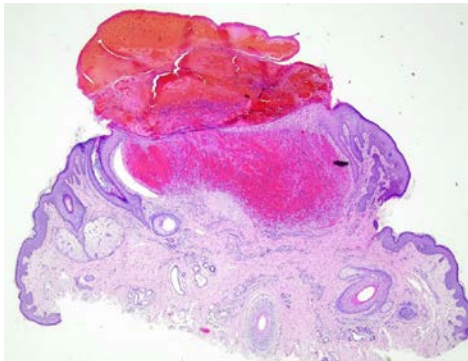
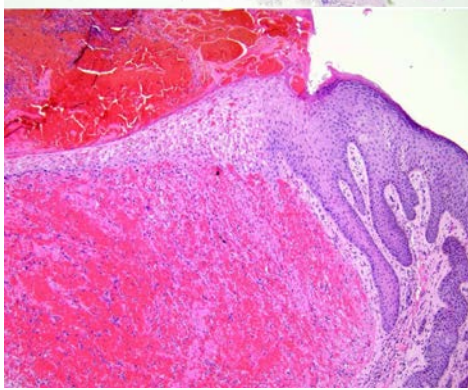


週	日期	時間	活動	Case of the week
一	06/03	12:00-13:00	※ 皮膚癌症團隊會議 (3F門診討論室)	A female around age of 40 shows multiple red papules and nodules on perineum for 7 years.
二	06/04	08:00-08:30	※ 臨床病例討論會 R1 侯秉宸 (3F門診討論室) 【全科人員】 1. Management of urticarial dermatitis and dupilumab induced injection reaction /VS 許釗凱 2. Cutaneous non-tuberculous mycobacterial infection after thread lifting /VS 劉威廷	
		08:30-09:00	※ 出院病例討論會 R1 張藝瀚 (3F門診討論室) 【全科人員】	
三	06/05	08:00-09:00	※ 住診教學 VS 劉威廷 (3F門診討論室) 【Clerks, PGYs, Rs】	 
		13:00-15:00	※ 臨床病理討論會 (括弧內為討論重點) R2 賴奕慈 / VS 李玉雲 (3F門診討論室) 【全科人員】 1. Skin, perineum, biopsy: Lichen sclerosus et atrophicus. ( <a href="#">The clinicopathology review of lichen sclerosus et atrophicus.</a> ) /VS 趙曉秋 2. Skin and soft tissue, elbow, right, excision: Calcinosis cutis, suggestive of tumoral calcinosis. ( <a href="#">The clinicopathology review of calcinosis cutis.</a> ) /VS 廖怡貞 3. Skin, leg, right, biopsy: Stevens-Johnson syndrome background with impetigo-like change. ( <a href="#">The clinicopathology review of methotrexate-induced skin toxicity.</a> ) /VS 何英右 4. Skin, forearm, left; biopsy: Verruca vulgaris. ( <a href="#">The clinicopathology review and treatment of epidermodysplasia verruciformis.</a> ) /VS 杜威廷 5. Skin, left palm, biopsy: Epidermolytic hyperkeratosis. ( <a href="#">The clinicopathology review of palmoplantar keratoderma.</a> ) /VS 杜威廷 6. Soft tissue, little finger, right, excision: Giant cell tumor of tendon sheath. ( <a href="#">The clinicopathology review of giant cell tumor of tendon sheath.</a> ) /VS 趙曉秋	
		08:00-08:30	※ 皮膚外科期刊討論會 (3F門診討論室) 【全科人員】 Long-Term Improvement of Different Types of Acne Vulgaris Using a Mild Photodynamic Therapy Protocol with BF-200 ALA Gel: A Series of Cases (J Clin Med . 2024 May 1;13(9):2658) R2 賴奕慈/ VS 何英右	
		08:30-09:00	※ 皮膚期刊討論會 (3F門診討論室) 【全科人員】 Noninvasive treatment of cutaneous neurofibromas (cNFs): Results of a randomized prospective, direct comparison of four methods (J Am Acad Dermatol . 2024 Apr;90(4):767-774) R3 王瀚棠/ VS 劉威廷	
		08:00-09:00	※ 住院醫師讀書會: Fitzpatrick 9e Ch. 49, 50, 51 R2 曾怡倫 (3F門診討論室) 【Rs】	
		06/08	※ 值班主治醫師查房	
日	06/09			Answer for last week: eosinophilic cellulitis