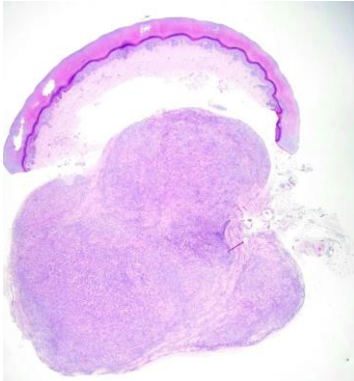
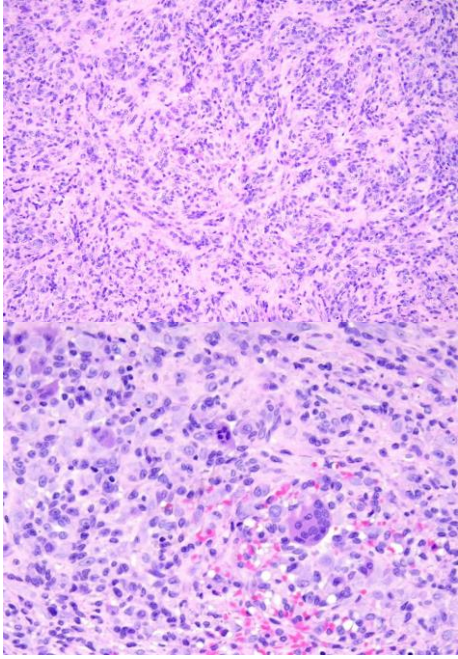


週	日期	時間	活動	Case of the week
一	06/17			
二	06/18	08:00-08:30	※ 臨床病例討論會 R2 曾怡倫 (3F門診討論室) 【全科人員】 1. The clinicopathology review of extragenital lichen sclerosis VS 廖怡貞 2. The clinicopathology review of unusual lichen planus with predominate plasma cell infiltrate VS 許釗凱	A 30 y/o female presented with an asymptomatic 0.6x0.5 cm elastic to firm nodule on right 5th finger for months.
		08:30-09:00	※ 出院病例討論會 R1 侯秉宸 (3F門診討論室) 【全科人員】	
三	06/19	08:00-09:00	※ 住診教學 VS 劉威廷 (3F門診討論室) 【Clerks, PGYs, Rs】	
		13:00-15:00	※ 臨床病理討論會 (括弧內為討論重點) R1 張藝瀚 / VS 李玉雲 (3F門診討論室) 【全科人員】 1. Skin, lateral chest, right, biopsy: Compatible with reactive perforating collagenosis. (The clinicopathology review of reactive perforating collagenosis.) /VS 許釗凱 2. Skin, foot, right, biopsy: Spongiotic psoriasiform dermatitis. (The clinicopathology review of palmoplantar psoriasis vs pompholyx.) /VS 趙曉秋 3. Skin, chest; biopsy with DIF: Compatible with bullous pemphigoid. (The clinicopathology review of dipeptidyl peptidase 4 inhibitors (DPP4i)-associated bullous pemphigoid.) /VS 趙曉秋 4. Skin, palm, right, biopsy: Kaposi sarcoma.. (The clinicopathology review of Kaposi sarcoma.) /VS 許明隆 5. Skin, back, left; biopsy: Neurofibroma.. (The clinicopathology review of neurofibroma and survey of neurofibromatosis type 1.) /R4 黃信奮 6. Skin, face, left; excision: Arteriovenous hemangioma (cirroid aneurysm).. (The clinicopathology review of arteriovenous malformation.) /VS 趙曉秋	
		08:00-08:30	※ 外訓醫師報告 Extramammary Paget's disease (3F門診討論室) 【全科人員】 成大家醫R2 王偉如 / VS 何英右	
		08:30-09:00	※ 主治醫師演講 Recent updates in medical dermatology (3F門診討論室) 【全科人員】 VS 杜威廷	
		08:00-09:00	※ 住院醫師讀書會: Fitzpatrick 9e Ch. 77 R4 林謙 (3F門診討論室) 【Rs】	
四	06/20			
五	06/21			
六	06/22			
日	06/23			

Answer for last week:  
secondary syphilis.