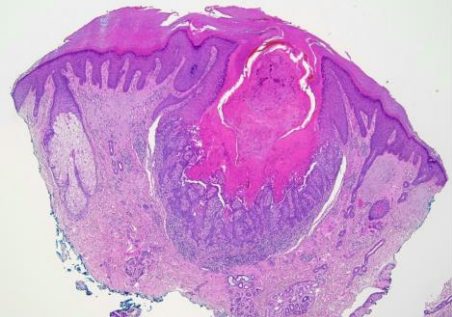
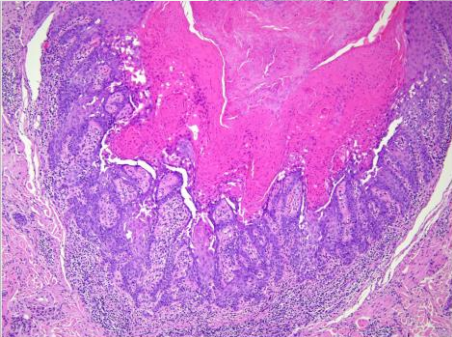
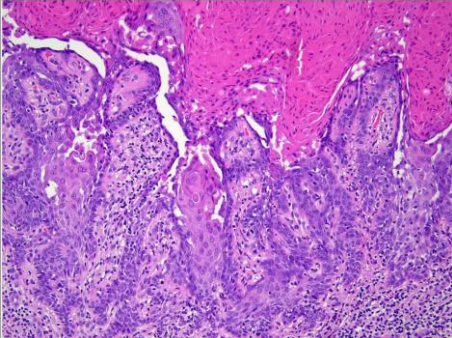


週	日期	時間	活動	Case of the week
一	06/24	12:00-13:00	※ 玉山學者演講 (醫學院第一講堂) How to develop your career and leadership skills Prof John A McGrath	A 70 y/o male referred from a local clinic presented with a 0.5 cm round hyperkeratotic papule with telangiectasia on face for 1 year.   
二	06/25	08:00-08:30	※ Research seminar (3F門診討論室)【全科人員】 Mammary Paget Disease: A Single Center-Based Clinicopathologic Study R1 侯秉宸 / VS 李玉雲	
		08:30-09:00	※ 主治醫師演講 (3F門診討論室)【全科人員】 Drug reaction with eosinophilia and systemic symptoms (DRESS) syndrome: More than just a rash VS 趙曉秋	
三	06/26	08:00-09:00	※ 住診教學 VS 劉威廷 (3F門診討論室)【Clerks, PGYs, Rs】	
		13:00-15:00	※ 臨床病理討論會 (括弧內為討論重點) VS 李玉雲 (3F門診討論室)【全科人員】 1. Skin, abdomen; biopsy: Compatible with epidermolysis bullosa.. (The clinicopathology review of anti-inflammatory treatment for recessive dystrophic epidermolysis bullosa) R3 王瀚棠/ VS 許釗凱	
			2. Skin, dorsal foot, right, biopsy: Epidermal necrosis with vessel thrombosis. (The clinicopathology review of JAK inhibitor in livedoid vasculopathy) R1 張藝瀚/ VS 許釗凱 3. Skin, right hand; punch biopsy: Peri-sweat gland lymphocytic infiltration. (The clinicopathology review of JAK inhibitor in idiopathic acquired anhidrosis.) R1 張藝瀚/ VS 許釗凱	
四	06/27	08:00-09:00	※ 全院CPC (第四講堂)【全科人員】 病例：A 49-year-old woman with headache, nausea, and vomiting for 3 days.	
五	06/28	08:00-09:00	※ 住院醫師讀書會: Fitzpatrick 9e Ch. 78, 80 R1 侯秉宸 (3F門診討論室)【Rs】	
六	06/29		※ 值班主治醫師查房	
日	06/30		※ 值班主治醫師查房	Answer for last week: Giant cell tumor of tendon sheath.