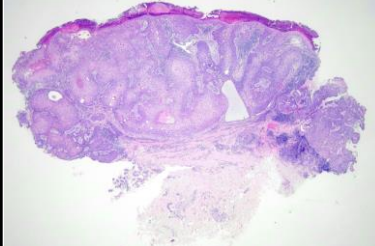
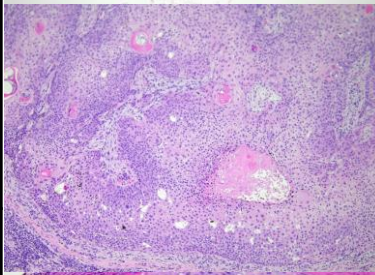


週	日期	時間	活動	Case of the week
一	08/05	12:00-13:00	※ 皮膚癌症團隊會議 (3F門診討論室)	A 70 y/o F presented with one 4-cm irregular pigmented nodule on right chest for 2 months..    
二	08/06	08:00-09:00	※ 研究討論會 (3F門診討論室) 【全科人員】 1. Fixed drug eruption - a retrospective review of 146 patients in NCKUH R4 葉芮苡 2. Taiwanese Dermatological Association Consensus on the Diagnosis and Management of Alopecia Areata VS 楊朝鈞 交換學生自我介紹：Julien Canniccioni VS 王德華	
三	08/07	08:00-09:00	※ 住診教學 VS 杜威廷 (3F門診討論室) 【Clerks, PGYs, Rs】	
		13:00-15:00	※ 臨床病理討論會 (括弧內為討論重點) R2 侯秉宸 / VS 李玉雲 (3F門診討論室) 【全科人員】 1. Skin, palm, left; biopsy: Consistent with graft-versus-host-disease. (The clinicopathology review of acute graft-versus-host-disease versus morbilliform drug eruption) /VS 楊朝鈞 2. Soft tissue, axilla, right; shave biopsy: Juvenile xanthogranuloma. (The clinicopathology review of juvenile xanthogranuloma and differential diagnosis) /VS 李玉雲 3. Skin, wrist, left; biopsy: Lymphoma, compatible with mycosis fungoides with large cell transformation. (The clinicopathology review of mycosis fungoides with large cell transformation) /VS 趙曉秋 4. Skin, area with whitening hair; biopsy: Poliosis with vitiligo change. (The clinicopathology review of follicular vitiligo and the differential diagnosis of poliosis circumscripta) /VS 許釗凱 5. Skin, abdomen, biopsy: Minimal histologic change. (The clinicopathology review of interstitial lung disease, nephrotic syndrome and epidermolysis bullosa (ILNEB)) /VS 許釗凱 6. Skin, hand, left; biopsy: Compatible with bullous pemphigoid. (The clinicopathology review of dyshidrosiform bullous pemphigoid and the relation to scabies infestation) /VS 劉威廷	
		15:30-16:30	廠商演講：Boehringer Ingelheim 高雄長庚 New treatment Era - Spevigo for Generalized Pustular Psoriasis 曾涵琪醫師	
		08:00-08:30	※ 皮膚外科期刊討論會 (3F門診討論室) 【全科人員】 Suture Net Technique for Mid-face Superficial Fat Compartments Restoration (Dermatol Surg. 2024 Jul 1;50(7):643-649.) R3 賴奕慈/ VS 何英右	
四	08/08	08:30-09:00	※ 皮膚期刊討論會 (3F門診討論室) 【全科人員】 A Practical Guide to Using Biologics in Pediatric Dermatology. R4 王瀚棠/ (J Cutan Med Surg. 2024 Jan-Feb;28(1):59-67) VS 趙曉秋	
五	08/09	08:00-09:00	※ 住院醫師讀書會: Fitzpatrick 9e Ch 88, 89, 90 R4 葉芮苡 (3F門診討論室) 【Rs】	
六	08/10		※ 值班主治醫師查房	Answer for last week: Trichoepithelioma
日	08/11			