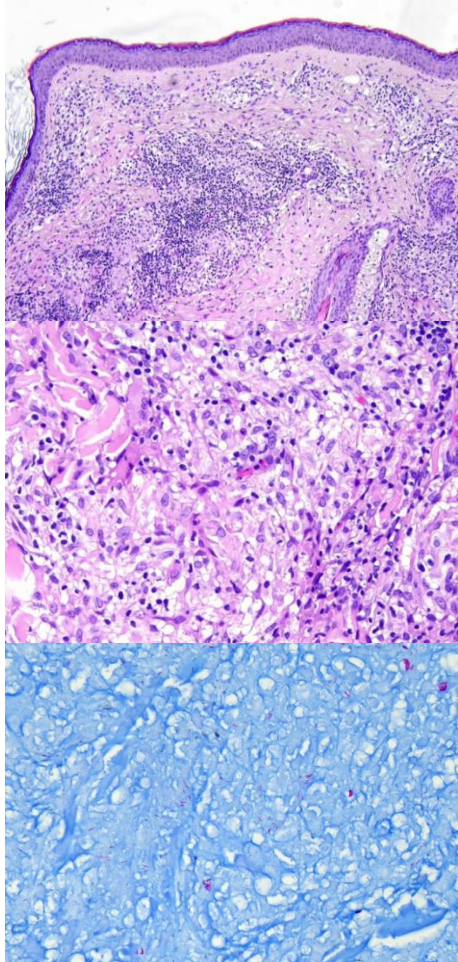


週	日期	時間	活動	Case of the week	
一	08/12			Multiple infiltrative papules and plaques for 1 month in a 30 y/o male.	
二	08/13	08:00-08:30	※ 臨床病例討論會 R1 李孟矜 (3F門診討論室) 【全科人員】 1. Review of cutaneous manifestations of angioimmunoblastic T-cell lymphoma /VS 楊朝鈞 2. Review of treatment options for pyoderma gangrenosum /VS 李玉雲		
		08:30-09:00	※ 出院病例討論會 R1 鄭宇宸 (3F門診討論室) 【全科人員】 ※ 住診教學 VS 杜威廷 (3F門診討論室) 【Clerks, PGYs, Rs】		
三	08/14	13:00-15:00	※ 臨床病理討論會 (括弧內為討論重點) R2 張藝瀚 / VS 李玉雲 (3F門診討論室) 【全科人員】 1. Skin, chest/breast, right, biopsy: Adenocarcinoma. (The clinicopathology review of primary cutaneous apocrine carcinoma vs direct extension of breast carcinoma to the skin) /VS 趙曉秋 2. Skin and soft tissue, forearm, left, excision: Calcinosis cutis. (The clinicopathology review of calcinosis cutis.) /VS 何英右 3. Skin, thigh, left, biopsy: Pityriasis lichenoides chronica. (The clinicopathology review of pityriasis lichenoides chronica.) /VS 李玉雲 4. Skin, nose tip; shave biopsy: Hidrocystoma. (The clinicopathology review of apocrine and eccrine hidrocystoma.) /VS 王德華 5. Skin, forearm, left, biopsy: Myofibroblastic proliferation, compatible with nodular fasciitis. (The clinicopathology review of nodular fasciitis.) /VS 杜威廷 6. Skin, foot, left, biopsy: Atypical squamous cells. (The clinicopathology review of HPV related Bowen disease.) /VS 朱家葆		
四	08/15	08:00-09:00	※ 感染管制課程(申請院內學分) (3F門診討論室) 【全科人員】 法定傳染病之通報流程 (M痘、漢生病、梅毒、登革熱) 感管中心郭于嘉感管師		
五	08/16	08:00-09:00	※ 住院醫師讀書會: Fitzpatrick 9e Ch 91 R4王瀚棠 (3F門診討論室) 【Rs】		Fite and acid-fast stain: bright red bacilli.
六	08/17		※ 值班主治醫師查房		Answer for last week: pigmented porocarcinoma.
日	08/18				