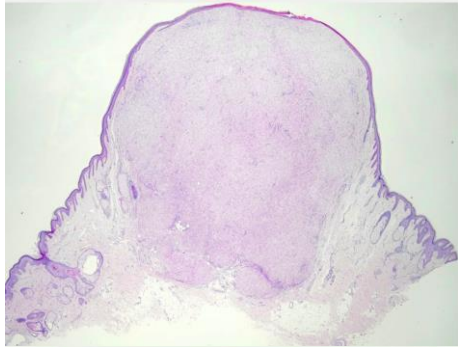
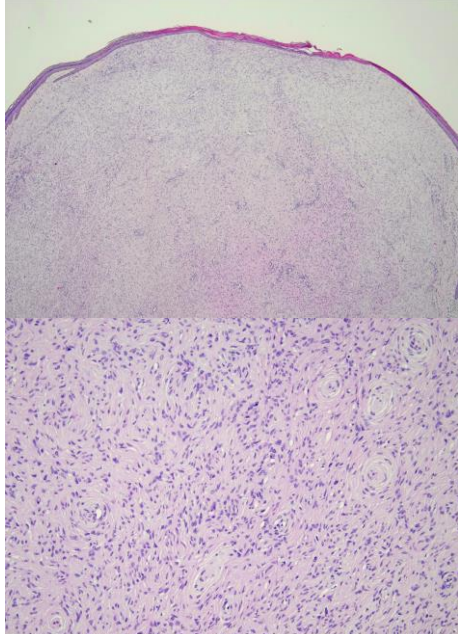


週	日期	時間	活動	Case of the week
一	08/26			A 27 y/o M presented with a 0.6 cm reddish papule on right preauricular area for 1 year.
二	08/27	08:00-08:30	※ 臨床病例討論會 R1 李孟羚 (3F門診討論室) 【全科人員】 1. Review of clinical characteristics and treatment for 20 nail dystrophy VS 王德華 2. Review of streptococcal toxic shock syndrome: clinical manifestations and management VS 趙曉秋	
		08:30-09:00	※ 出院病例討論會 R1 鄭宇宸 (3F門診討論室) 【全科人員】	
三	08/28	08:00-09:00	※ 住診教學 VS 杜威廷 (3F門診討論室) 【Clerks, PGYs, Rs】	
		13:00-15:00	※ 臨床病理討論會 (括弧內為討論重點) R2 張藝瀚 / VS 李玉雲 (3F門診討論室) 【全科人員】 1. Skin, index finger, right; excision: Eccrine poroma. (The clinicopathology review of poroma) /VS 劉威廷 2. Skin, leg, right; biopsy: Spongiotic dermatitis. (The clinicopathology review of elephantiasis nostras verrucosa.) /VS 許明隆 3. Skin, arm, left; biopsy: Spongiotic psoriasiform dermatitis with impetigo.. (The clinicopathology review of f bullous impetigo.) /VS 廖怡貞 4. Skin, forearm, left, punch biopsy: Compatible with involuting nodular Kaposi sarcoma. (The clinicopathology review of involution of Kaposi sarcoma.) /VS 李玉雲 5. Skin, chest, left, biopsy: Vacuolar interface dermatitis. (The clinicopathology review of drug reaction with eosinophilia and systemic symptoms.) /VS 朱家葆 6. Skin, penile shaft; excision: Consistent with bowenoid papulosis. (The clinicopathology review of bowenoid papulosis.) /VS 廖怡貞	
		15:30-16:30	※ 廠商演講Lilly Considering the Impact of Plaque Psoriasis in Challenging Body Area 新竹台大 邱顯鎰醫師	
		08:00-09:00	※ NP衛教：皮膚澱粉樣變性苔癬 (3F門診討論室) 【全科人員】 NP 王愛怡 / VS 廖怡貞 ※ 外訓醫師報告：Overview of sun protection 家醫科R2 鄭鴻怡 / VS 朱家葆	
五	08/30	08:00-09:00	※ 住院醫師讀書會: Fitzpatrick 9e Ch. 96, 97, 98, 99 (3F門診討論室) 【Rs】 R3 曾怡倫	IHC: weakly positive for EMA and CD34, negative for S100, desmin and actin.
六	08/31			
日	09/01		※ 值班主治醫師查房	Answer for last week: HPV related Bowen disease