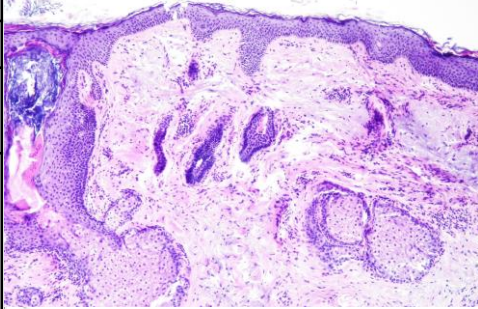
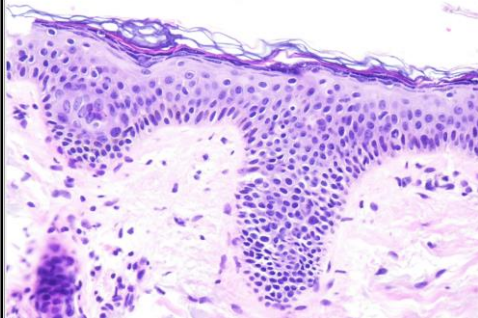


週	日期	時間	活動	Case of the week
一	10/07	08:30-09:00	※ 小科會 (3F醫師辦公室) 【VS 楊朝鈞、Rs】	An 83 y/o female showed an asymptomatic 0.4 cm flesh color papule with peripheral telangiectasia on right cheek for 6 months.
		12:00-13:00	※ 皮膚癌症團隊會議 (3F門診討論室)	
二	10/08	08:00-08:30	※ 研究討論會 (3F門診討論室) 【全科人員】 1. Immunoproteomic Response to IL-17A Blockade in a Patient with Generalized Pustular Psoriasis: New Insights from Plasma Olink Profiling R1 鄭宇宸/ VS 許釗凱	
		08:30-09:00	※ 出院病例討論會 R1 李孟羚 (3F門診討論室) 【全科人員】	
三	10/09	08:00-09:00	※ 住院醫師讀書會: Fitzpatrick 9e Ch. 108, 110 (3F門診討論室) 【Rs】 R1 鄭宇宸	
		13:00-15:00	※ 臨床病理討論會 (括弧內為討論重點) R2 侯秉宸 / VS 李玉雲 (3F門診討論室) 【全科人員】	
			1. Skin, buttock, right, excision: Calcinosis cutis (The clinicopathology review of calcinosis cutis.) /VS 許明隆	
			2. Skin, thigh, left, biopsy: Superficial and deep perivascular infiltrates with eosinophils and atypical lymphocytes. (The clinicopathology review of eosinophilic dermatosis of hematologic malignancy) /VS 楊朝鈞	
			3. Skin, scalp, left (anterior); biopsy: Benign sebaceous lesion, suggestive of sebaceous mantleoma. (The clinicopathology review of sebaceous mantleoma.) /VS 許釗凱	
			4. Skin, thigh, right, excision: In favor of intraepidermal spitz nevus with pagetoid spread. (The clinicopathology review of pagetoid spitz nevus.) /VS 杜威廷	
5. Skin, back, biopsy: Neurofibroma. (The clinicopathology review of plexiform neurofibroma and neurofibromatosis.) /VS 林謙				
6. Skin, cheek, left, biopsy: Perivascular dermatitis with increased dermal mucin, compatible with tumid lupus erythematosus. (The clinicopathology review of tumid lupus erythematosus) /VS 朱家葆				
15:00-15:30	※ UCB 廠商演講 Cimzia for psoriatic arthritics and psoriasis			
17:30-18:30	※ 科部會議 (線上) 【VS、CR】			
四	10/10		※ 國慶日休假 ※	
五	10/11	08:00-09:00	※ 住診教學 VS 楊朝鈞 (3F門診討論室) 【Clerks, PGYs, Rs】	
六	10/12		※ 值班主治醫師查房	Answer for last week: gouty tophi.
日	10/13			