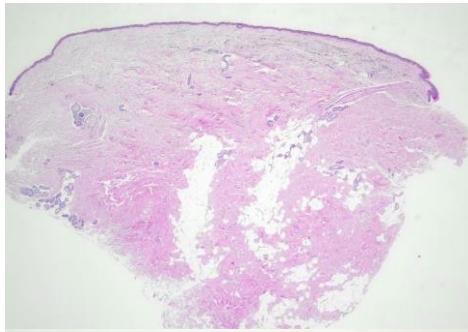
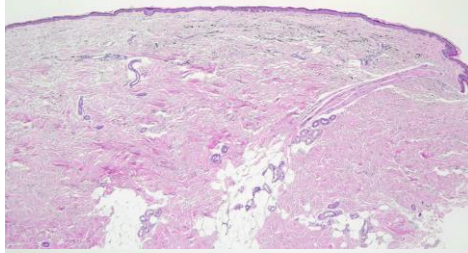
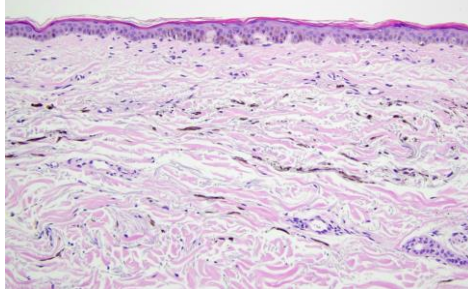
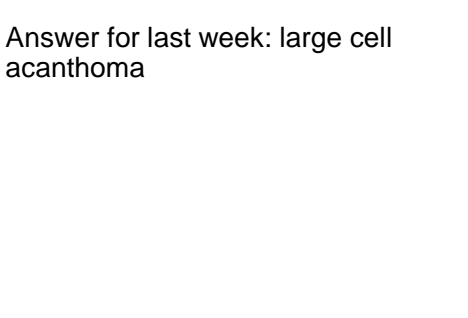


週	日期	時間	活動	Case of the week			
一	10/14						
二	10/15	08:00-08:30	※ 臨床討論會 R1 李孟矜 (3F門診討論室) 【全科人員】 1. Review the clinical course of a folliculotropic mycosis fungoides case /VS 楊朝鈞 2. Overview of Pthirus pubis /VS 杜威廷	A 79 y/o M showed fine pigmented macules on bilateral shoulders for 2 years. 			
		08:30-09:00	※ 出院病例討論會 R1 鄭宇宸 (3F門診討論室) 【全科人員】				
三	10/16	08:00-09:00	※ 住院醫師讀書會: (3F門診討論室) 【Rs】 Fitzpatrick 9e Ch. 115 R3 曾怡倫	 			
		13:00-15:00	※ 臨床病理討論會 (括弧內為討論重點) R2 張藝瀚 / VS 李玉雲 (3F門診討論室) 【全科人員】 1. Skin, thumb, right; excision: Ganglion. (The clinicopathology review of ganglion and differential diagnosis.) /VS 趙曉秋 2. Skin, waist, left, biopsy: Carcinoma, metastatic. (The clinicopathology review of cutaneous metastasis of ovarian carcinoma.) /VS 劉威廷 3. Skin, forearm, left, biopsy: Lobar panniculitis. (The clinicopathology review of panniculitis and differential diagnosis.) /VS 劉威廷 4. Skin, occipital scalp, biopsy: Compatible with nuchal type fibroma. (The clinicopathology review of nuchal type fibroma.) /R4 王瀚棠 5. Skin, thigh, right; biopsy with direct immunofluorescence: Suggestive of auto-erythrocyte sensitization syndrome. (The clinicopathology review of auto-erythrocyte sensitization syndrome.) /VS 廖怡貞 6. Skin, thigh, right; biopsy with direct immunofluorescence: Compatible with bullous fixed drug eruption with toxic epidermal necrolysis-like features. (The clinicopathology review of TEN-like generalized bullous fixed drug eruption.) /VS 趙曉秋				
					※ 期刊討論會: (3F門診討論室) 【全科人員】 1. Full-course NIR-II imaging-navigated fractionated photodynamic therapy of bladder tumours with X-ray-activated nanotransducers (Nat Commun. 2024 Sep 19;15(1):8240.) R3 曾怡倫 /VS 王德華 2. A Versatile Cryomicroneedle Patch for Traceable Photodynamic Therapy (Adv Mater. 2024 Sep;36(36):e2400933.) R1 鄭宇宸 /VS 王德華 ※外科期刊討論會: Reconstructing Nasal Defects With Acellular Dermal Matrix After Mohs Micrographic Surgery: A 12-year Experience (Dermatol Surg. 2024 Sep 1;50(9):814-820.) R1 李孟矜 /VS 何英右		
四			10/17		08:00-09:00		Answer for last week: large cell acanthoma 
五			10/18		08:00-09:00	※ 住診教學 VS 楊朝鈞 (11B會議室) 【Clerks, PGYs, Rs】	
六			10/19			※ 值班主治醫師查房	
日	10/20						