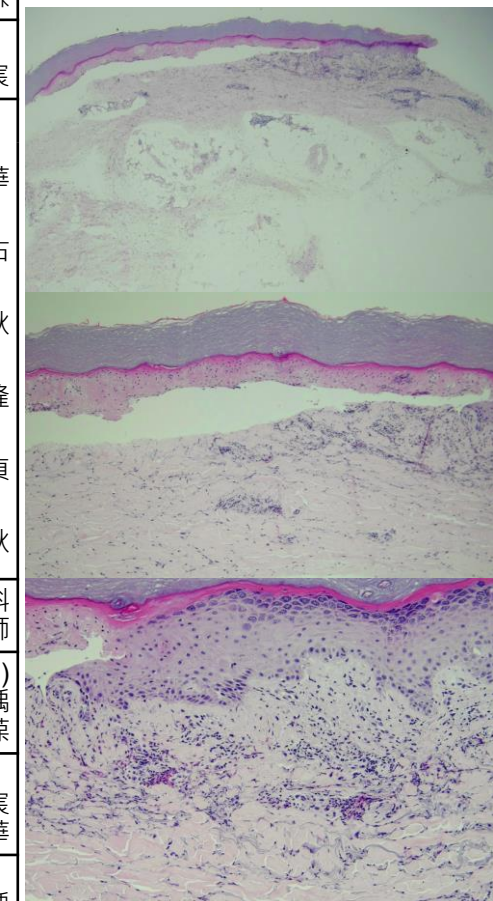


週	日期	時間	活動
一	10/28		
二	10/29	08:00-08:30	※ 研究討論會 (3F門診討論室) 【全科人員】 Review of pustular psoriasis VS 廖怡貞
		08:30-09:00	※ 臨床病例討論會 R1 鄭宇宸(3F門診討論室) 【全科人員】 1. Review of intradermal test /VS 劉威廷 2. Treatment of prurigo pigmentosa /VS 林謙
三	10/30	08:00-09:00	※ 住院醫師讀書會: (3F門診討論室) 【Rs】 Fitzpatrick 9e Ch. 116 R2 侯秉宸
		13:00-15:00	※ 臨床病理討論會 (括弧內為討論重點) R2 張藝瀚 / VS 李玉雲 (3F門診討論室) 【全科人員】
			1. Skin, chest; biopsy: Consistent with lupus erythematosus. (The clinicopathology review of cutaneous lupus erythematosus.) /VS 王德華
2. Skin, nose, left; biopsy: Granulomatous inflammation. (The clinicopathology review of granulomatous rosacea.) /VS 何英右			
3. Skin, upper lip, left, punch biopsy: Compatible with trichofolliculoma. (The clinicopathology review of trichofolliculoma and differential diagnosis.) /VS 趙曉秋			
4. Skin, lower lip; biopsy: (1) Verrucous hyperplasia. (2) Superficial fungal infection. (The clinicopathology review of oral verrucous hyperplasia.) /VS 許明隆			
5. Skin, sole, left; excision: Acral nevus with architectural atypia. (The clinicopathology review of dysplastic nevus on the volar skin.) /VS 廖怡貞			
6. Skin, axilla, right, biopsy: Compatible with lichen sclerosus et atrophicus. (The clinicopathology review of lichen sclerosus et atrophicus.) /VS 趙曉秋			
15:30-16:30	※ 廠商演講: B型肝炎的治療 成大內科 鄭斌男醫師		
四	10/31	08:00-08:20	※ PGY醫師報告: (3F門診討論室) Treatment options for severe hidradenitis suppurativa in patients with end-stage renal disease. PGY 張芝瑀 /VS 朱家葆
		08:20-08:35	※ 期刊討論會: Predicting adjuvant radiation therapy benefit in cutaneous squamous cell carcinoma with the 40-gene expression profile. (Future Oncol. 2024 Sep 4:1-10.) R2 侯秉宸 /VS 王德華
		08:35-09:00	※ TDA/TSID年會預報: 1. TSID 口頭報告: 12分鐘報告 (8分鐘報告 + 4分鐘討論) PGY 張芝瑀 2. TDA 病例報告: 8分鐘報告 (6分鐘報告 + 2分鐘討論) R4 王瀚棠 3. TDA 研究論文: 12分鐘報告 (10分鐘報告 + 2分鐘討論) R4 葉苾苒
五	11/01	08:00-09:00	※ 住診教學 VS 楊朝鈞 (3F門診討論室) 【Clerks, PGYs, Rs】
六	11/02		
日	11/03		※ 值班主治醫師查房

Case of the week
A 90 y/o male had history of gout, diabetes mellitus and heart failure. He presented with generalized erythematous blister formation for 3 day. The itching rash appeared after he took 1 pack of over-the-counter medication for common cold.



Answer for last week: Carcinoma, compatible with metastatic breast cancer, with comedonecrosis.