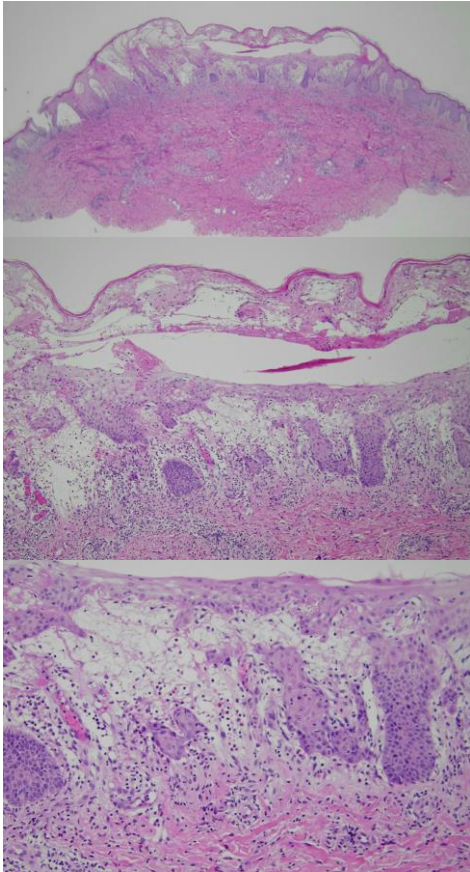


週	日期	時間	活動	Case of the week
一	3/31			<p>A young adult male presented with fever and extensive vesicular to bullous lesions on limbs and palmoplantar area for a week.</p> 
二	4/01	08:00-08:30	※ 臨床討論會 R1 鄭宇宸 (3F門診討論室) 【全科人員】 1. A case of palmoplantar pustulosis favor SAPHO syndrome-related /VS 劉威廷 2. Erythema annulare centrifugum and differential diagnosis of annular skin lesions /R4 葉芮苙	
		08:30-09:00	※ 出院病例討論會 R1 李孟羚 (3F門診討論室) 【全科人員】	
三	4/02	08:00-09:00	※ 住診教學 VS 朱家葆 (11B會議室) 【Clerks, PGYs, Rs】	
		13:00-15:00	※ 臨床病理討論會 (括弧內為討論重點) R2 張藝瀚 / VS 李玉雲 (3F門診討論室) 【全科人員】 1. Skin, heel, left, excision: Plexiform schwannoma. (The clinicopathology review of plexiform schwannoma.) /VS 許明隆 2. Skin, posterior thigh, left, excision: Kaposi sarcoma. (The clinicopathology review of angiomatous Kaposi sarcoma.) /VS 杜威廷 3. Skin, trunk, biopsy: Lichenoid dermatitis. (The clinicopathology review of generalized eruptive histiocytosis and its differential diagnosis.) /VS 趙曉秋 4. Skin, nipple, right, biopsy: Hyperpigmentation. (The clinicopathology review of nevoid hyperkeratosis of nipple and areola.) /VS 趙曉秋 5. Skin, hand, right, biopsy: Interface dermatitis, vacuolar type. (The clinicopathology review of papular mucinosis.) /VS 楊朝鈞 6. Skin, abdomen, left, biopsy: Pemphigus, superficial. (The clinicopathology review of pemphigus foliaceus and its differential diagnosis.) /R4 王瀚棠	
四	4/03			<p>Answer for last week: hibernoma</p>
五	4/04		清明連假	
六	4/05		※ 值班主治醫師查房	
日	4/06			