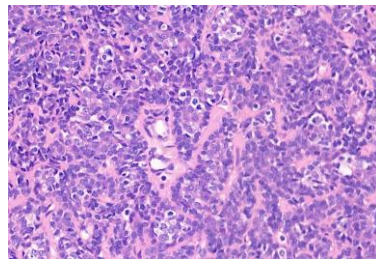


週	日期	時間	活動	Case of the week
一	07/14	12:00-13:00	※ 皮膚癌團隊會議 (3F門診討論室)【全科人員】	A 2.5cm elastic nodule on the right neck for several years.   
二	07/15		※ 臨床病例討論會 R2 侯秉宸/R2 張藝瀚 (3F門診討論室)【全科人員】	
		08:00-08:30	1. Clinicopathological review of juvenile circumscribed pityriasis rubra pilaris /VS 杜威廷 2. Cutaneous metastasis presenting as multiple annular erythema /VS 李玉雲	
		08:30-09:00	※ PGY seminar PGY才芷伶/ VS 楊朝鈞 (3F門診討論室)【全科人員】 Medical Ethics Reflection: Can Patients Reclaim Their Amputated Limbs After Surgery?	
三	07/16	08:00-09:00	※ 住診教學 VS 楊朝鈞 (3F門診討論室)【Clerks, PGYs, Rs】	
		13:00-15:00	※ 臨床病理討論會 (括弧內為討論重點) R1 鄭宇宸 / VS 李玉雲 (3F門診討論室)【全科人員】	
			1. Skin, lower abdomen, right, biopsy:Superficial perivascular dermatitis, possibly drug eruption. (The clinicopathology review of secondary syphilis) /VS 許釗凱	
			2. Skin, thigh, left, biopsy:Ulcer, compatible with reactive perforating collagenosis (The clinicopathology review of acquired reactive perforating collagenosis) /VS 許釗凱	
			3. Skin, lateral thigh, right, biopsy: Compatible with ruptured epidermal keratinous cyst, inflamed. (The clinicopathology review of M. abscessus) /VS 劉威廷	
			4. Skin, thigh, right, biopsy:Interface dermatitis, compatible with fixed drug eruption. (The clinicopathology review of fixed drug eruption) /VS 廖怡貞	
			5. Skin, ankle, left; biopsy:Kaposi sarcoma, nodular stage. (The clinicopathology review of Kaposi sarcoma) /VS 趙曉秋	
	6. Skin, face, right, excision:Trichilemmoma. (The clinicopathology review of trichilemmoma) /VS 劉威廷			
	15:00-16:00	※ 轉診病例討論會 (3F門診討論室)【全科人員】		
四	07/17	18:00-19:00	※ 醫美注射教學 VS林宏謙 (3F門診討論室)【Rs】	Answer for last week: Pilonidal cyst
五	07/18	08:00-09:00	※ 住院醫師讀書會: Fitzpatrick 9e Ch. 180, 181 R2 張藝瀚 (3F門診討論室)【Rs】	
六	07/19		※ 值班主治醫師查房	
日	07/20			