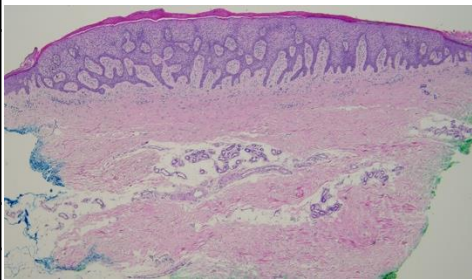
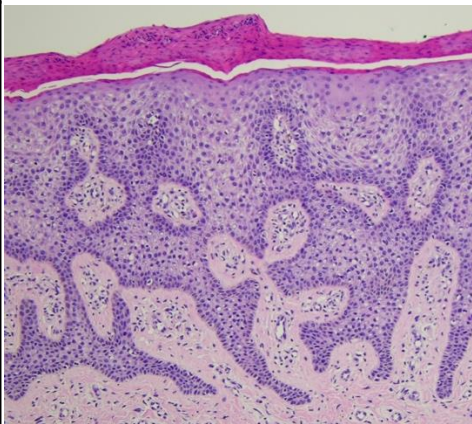


週	日期	時間	活動	Case of the week	
一	12/15	08:00-08:50	※ 皮美外讀書會: Dermatologic Surgery Ch.12, 18-21 VS 劉威廷 (線上) 【皮美外受訓醫師】		
二	12/16	08:00-08:30	※ 臨床討論會 R1 張皓雲 (3F門診討論室) 【全科人員】 1. Tzanck smear revisited: Recognizing pagetoid cells and other key diagnostic features /VS 王德華 2. A case of erythema infectiosum presenting with initial unilateral facial erythema /VS 王德華		
		08:30-09:00	※ 出院討論會 R1 蘇宇昂 (3F門診討論室) 【全科人員】		
三	12/17	08:00-09:00	※ 住診教學 VS 杜威廷 (11B會議室) 【Clerks, PGYs, Rs】	 EMA & CEA: no cuticle ductal structure in the tumor	
		13:00-15:00	※ 臨床病理討論會 R2 李孟鈴 /VS 李玉雲 (3F門診討論室) 【全科人員】 1. Skin, parietal scalp, left; biopsy: Inflammatory alopecia, consistent with alopecia areata. (The clinicopathologic spectrum of alopecia areata with emphasis on the superacute stage) /VS 楊朝鈞 2. Skin, scrotum, biopsy: Psoriasiform dermatitis. (The clinicopathology review of inverse psoriasis) /VS 王德華 3. Skin, ankle, right, biopsy: Leukocytoclastic vasculitis. (The clinicopathology review of leukocytoclastic vasculitis with features of flagellate purpura) /VS 楊朝鈞 4. Skin, right sole, tumor excision: Poroma with atypical feature. (The clinicopathology review of eccrine poroma versus eccrine porocarcinoma) /VS 趙曉秋 5. Skin, lateral thigh, left; biopsy: Atypical lymphocytes. (The clinicopathology review of mycosis fungoides) /VS 楊朝鈞 6. Soft tissue, proximal nail matrix, right big toe; reconstruction: Glomus tumor. (The clinicopathology review of myxoid glomus tumor) /VS 杜威廷		
四	12/18			Answer for last week: Cystic pilomatricoma	
五	12/19	08:00-09:00	※ 住院醫師讀書會: Fitzpatrick 9e Ch. 10、13 R2 鄭宇宸 (3F門診討論室) 【Rs】		
六	12/20		※ 值班主治醫師查房		
日	12/21				