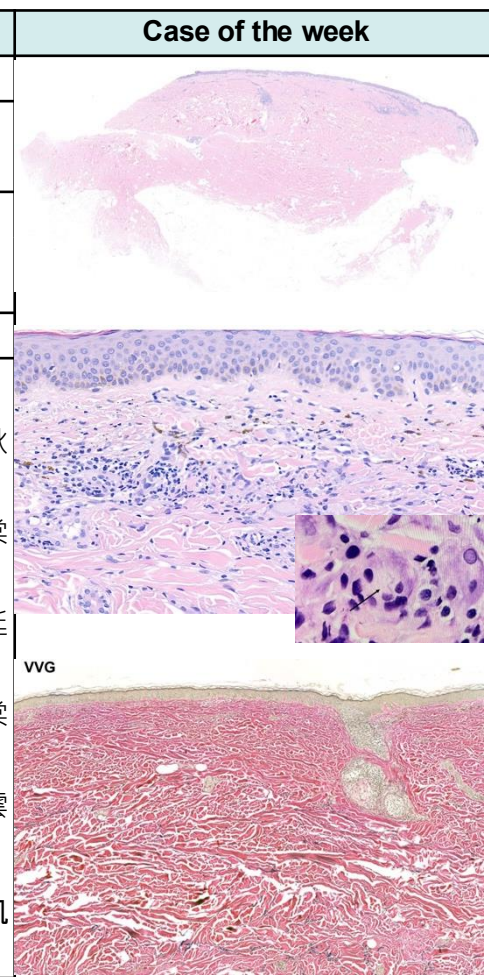


週	日期	時間	活動
一	04/27		
二	04/28	08:00-08:30	※ Research seminar VS 林謙 (3F門診討論室) 【全科人員】 Clinical Practice in Chronic Venous Disease: Practical Insights into Diagnosis and Management
		08:30-09:00	※ Research seminar R1 蘇宇昂 (3F門診討論室) 【全科人員】 Optimizing Dermatologic Workflow: A Digital Transformation of Clinical Documentation and Image Management
三	04/29	08:00-09:00	※ 住診教學 VS 楊朝鈞 (3F門診討論室) 【Clerks, PGYs, Rs】
		13:00-15:00	※ 臨床病理討論會 R2 李孟羚 /VS 李玉雲 (3F門診討論室) 【全科人員】
			1. Skin, forearm, left, excision: Warty dyskeratoma. (The clinicopathology review of warty dyskeratoma) /VS 趙曉秋
			2. Purpuric lichenoid dermatitis with interface change, necrotic keratinocytes, and periadnexal involvement, considering lichen striatus. (The clinicopathology review of lichen striatus) /VS 王瀚棠
3. Skin, forehead, left, biopsy: Spongiotic psoriasiform dermatitis. (The clinicopathology review of sebopsoriasis) /VS 杜威廷			
4. Skin, calf, left; biopsy: Abundant papillary dermal amyloid deposition and thin rete ridges with branching, suggestive of Dowling-Degos disease. (The clinicopathology review of Dowling-Degos disease) /VS 王瀚棠			
5. Skin, forearm, left; excision: Vascular neoplasm. (The clinicopathology review of adult-onset kaposiform hemangioendothelioma) /VS 李玉雲			
6. Soft tissue, left leg; biopsy: Superficial and deep perivascular dermatitis with granuloma, neutrophils and eosinophils, and patchy lobular panniculitis. (The clinicopathology review of reactive dermatosis related to anti-interferon-γ autoantibodies syndrome) /VS 許劍凱			
15:30-16:00	※ 廠商demo (八億) Mosaic 3D凍凝雷射		
四	04/30	08:00-09:00	※ 全院臨床病理討論會 (第四講堂) 【全科人員】
五	05/01		勞動節放假一天
六	05/02		
日	05/02		※ 值班主治醫師查房



Answer for last week: Verrucous carcinoma