

國立成功大學醫學院附設醫院
皮膚部醫學系學生臨床課程教學計畫書

	108/06/20 部室會議修訂通過 109/06/11 部室會議修訂通過 110/07/08 部室會議修訂通過 111/05/12 部室會議修訂通過 112/06/14 部室會議修訂通過	099/06/23 部務會議修訂通過 100/06/29 部務會議修訂通過 101/08/22 部務會議修訂通過 102/08/14 部務會議修訂通過 103/08/21 部務會議修訂通過 104/08/06 部室會議修訂通過 105/09/01 部室會議修訂通過 106/08/10 部室會議修訂通過 107/06/14 部室會議修訂通過
--	--	--

科目名稱：六年級皮膚學科實習 必修 選修

教師：成大皮膚部醫師名單(附件一)

總學分數：2 學分

實習醫學生教學課程召集人：成大皮膚部主任

聯絡地點：醫學院 6 樓皮膚科辦公室

聯絡電話：06-2353535 分機 5417

實習地點：成大醫院皮膚部門診及 11B 病房

壹、前言：(摘錄自「國立成功大學醫學院附設醫院醫學系學生臨床課程學習通則」)

一、因應國立成功大學醫學院（以下簡稱本校）醫學系教學上之需求，得安排學生至國立成功大學醫學院附設醫院（以下簡稱本院）接受醫學教育相關觀摩及實習，為使本校醫學系學生於本院進行臨床課程時有所遵循，特訂定本通則。

二、身分定義如下：

(一) 醫學生：本校醫學系一至四年級，其部分時間於醫院「觀摩學習」。

(二) 實習醫學生：本校醫學系五、六年級學生，其全部時間於醫院「臨床實習」。

三、醫學生之觀摩學習：

(一) 除表定課程進行之例行觀摩學習外，若課程需求安排至本院做觀摩學習，請事先向科部提出申請，科部同意後方能進入本院。

(二) 一年級、二年級以觀摩為主，體驗為輔；三年級、四年級以體驗為主，臨床技能為輔。

(三) 臨床學習包含簡單傷口換藥、體溫測量、血壓測量、手術刷手、無菌手套穿戴、病史詢問、理學檢查，其餘臨床技術先行觀摩學習，待進入臨床後再實際操作。

(四) 醫學生在臨床觀摩學習時，須在本院合格醫事及其相關人員現場指導下，方得進行課程學習。

四、實習醫學生之臨床實習：

(一) 在本院醫師指導下做臨床實習，適度參與醫療、檢查、值班或其他工作。

(二) 其相關規定須遵守「國立成功大學醫學院附設醫院實習醫學生臨床實習規範」。

五、臨床醫師帶醫學系學生進行臨床課程前，須先徵詢病人並取得同意；若對於病人有觸及隱私部位之各種檢查時，應有第三者在場，第三者應以與病人同性別之醫護人員為優先。

- 六、臨床課程皆需事先安排，若發生時間及空間之排擠性，以高年級學生優先於次年級學生，且須對於次年級學生有妥善安排。
- 七、學生應恪遵本院一切規定、相關法令及各科基於業務需要明訂之相關規定。於本院取得、知悉之訊息負有保守醫療秘密之義務，除經本院同意外，不得向第三人披露。
- 八、本通則經本院臨床醫學教育委員會會議通過後實施，修正時亦同。

貳、教學目標：

對於初次接觸皮膚科臨床工作的實習醫學生們，藉由 3 週的實習時間，在門診及皮膚部病房與住院醫師一起學習及值班，由最基本的皮膚結構認識、皮膚生理、皮膚病灶觀察描述、理學及實驗室檢查開始，逐步認識常見的皮膚疾病及其病理機轉。

依照「ACGME 六大核心能力」，皮膚部訂定教學目標如下：

一、醫學知識(Medical Knowledge)及技能

- (一) 學習皮膚組織結構及皮膚生理功能及其在人體所扮演的重要角色。
- (二) 學習皮膚科觀察病灶的方式並正確地描述皮膚病灶。
- (三) 正確及完整的病史詢問。
- (四) 藉由照片、圖片使學生認識常見皮膚疾病。
- (五) 藉由臨床實習時接觸初診病人來學習診斷皮膚病的準則及技巧。
- (六) 學習專題探討的能力，包括文獻查詢、整理病例與發表討論。
- (七) 從病人照護(Patient care)開始，從工作中學習及成長(Practice-based learning and improvement)，進而適應制度下之臨床工作(Systems-based practice)

二、人際關係及溝通技巧(Interpersonal and communication skills)

- (一) 具備對病患及家屬間的溝通表達能力。
- (二) 學習醫病關係及醫療倫理。

三、醫療專業特質及專業素養(Professionalism)

養成高度的學習動機及熱忱的服務精神，認真負責的工作態度及良好的人際關係。

參、課程內容大綱：(詳見附件二)

- 一、皮膚基本組織結構及生理功能
- 二、皮膚病灶特徵觀察與描述
- 三、皮膚特殊檢查與診斷
- 四、皮膚病理特徵與診斷
- 五、常見皮膚疾病的臨床特徵、診斷及治療

肆、實習內容與地點

一、病房實習(11B 病房)：

- (一) 與主治醫師、住院醫師、實習醫師組成醫療團隊，一同照護病人，參與醫療工作。
- (二) 每日利用上班時間跟隨住院醫師或自行訪視病人至少一次，並應記錄 admission note。
(附件三、四)
- (三) 協助住院醫師一起處理病患換藥、靜脈注射、抽血、插鼻胃管及導尿管等。
- (四) 每日查房時，需熟悉病患病況並簡短報告病患之病史或情況。
- (五) 協助病房住院醫師，追查及記錄所屬之 team 的病患其各項檢驗結果。

(六)醫學生須每週參加病房之住診教學活動，住診教學方式由輪值之主治醫師負責，針對 1~2 位住院病人，對住院醫師、PGY 學員及實習醫學生做深入個案討論，其內容包括病況、臨床資訊、病態生理變化及鑑別診斷臨床處置等之討論與解釋，並填寫於「住診教學紀錄表」中(附件五)，能符合 ACGME 六大核心能力之需求。

二、門診實習：

- (一)詢問初診病人的病史並做皮膚病灶描述，並由主治醫師指導病史詢問及皮膚病灶描述的正確度及確實性。
- (二)在主治醫師及診間住院醫師指導下，學習各項皮膚病灶觀察及學習 KOH、Tzanck smear、Gram's stain 及細菌和黴菌培養。(附件六)
- (三)不另安排特別在治療室觀摩的時間，不過鼓勵跟診時段亦可至治療室觀摩相關治療處置，亦允許為了多元學習規劃而更換跟診的診次。
- (四)學習與病人溝通的技巧並注意皮膚病對病人帶來的心理層面影響。
- (五)學習基本的顯微皮膚病理結構。
- (六)第三週週一早上可以自由研究查詢資料以便準備報告。

三、參加科內學術活動：

星期	時間	地點	活動名稱
星期二	AM 08:00~9:00	3F OPD	Case conference
星期三	AM 08:00~9:00	11B 護理站/討論室	Teaching round
星期三	PM 13:00~3:00	3F OPD	Clinicopathological conference
星期四	AM 08:00~9:00	3F OPD	Journal reading

四、夜間值班：皮膚部無夜間值班。

五、訓練概要：

每日晨間與主治醫師及住院醫師一同訪視病人，並做病情討論，協助住院醫師處理病人，門診開診後至門診跟診，詢問初診病人病史、跟隨主治醫師看診並在指導下進行一般的檢查及治療，門診結束後再回到病房訪視住院病人。

伍、評量方式與配分

- 一、學習前評量：請實習學生在實習前將皮膚病灶描述的講義熟讀，實習第 1 天將進行筆試，以瞭解學生對皮膚病灶觀察的掌握能力，此部分僅提供能力指標不列入最後實習評分計算。
- 二、臨床見習成績(100%)(2 學分)：
 - (一)由主治醫師及住院醫師共同評分(佔 85%)，評比項目包括學習態度(30%)、個人學識(30%)、臨床技能(25%)。
 - (二)醫學系規定 80 項臨床核心技能，皮膚科佔 7 項(10%)。
 1. 皮膚的檢查(Skin examination)
 2. 開立處方(Write a prescription)
 3. 溝通能力(包括與高齡與兒童病患溝通的能力)(Communication skills)
 4. 提供病人衛教的能力(Patient education)
 5. 搜尋及選取正確醫療資訊的能力(Literature appraisal)
 6. 口述報告(Presentation)的能力(Bedside and conference)
 7. 書寫的能力(Documentation)

(三)電子學習紀錄完整度(佔 15%)，實習結束前完成並上傳電子護照系統，包括

1. Mini-Cex 至少 1 份(1 分)
2. DOPS 至少 1 份(1 分：請填其他項附註「KOH examination」)
3. 門診初診紀錄至少 3 份(6 分)
4. 住診教學紀錄 1 份(1 分)
5. 住院病歷紀錄 1 份(2 分)
6. 李玉雲教授之教學紀錄 1 份(2 分)(範本請見附件七)
7. 臨床技能評估表全部完成(1 分)
8. 反思回饋(1 分)

三、Lecture 筆試成績(100%)(1 學分)：實習最後 1 天舉行。

(一) 幻燈片題 25 題(佔 25%)

(二) 由各授課之主治醫師及總醫師出題(佔 75%)

四、定義學習成效不良：筆試成績低於 75 分者，則進行加強學習指導課程。依照本科學習成效不良實習醫學生補強計畫及流程。(附件八)

五、學習反應及回饋：實習中隨時由總醫師及教學負責主治醫師注意學生學習情況並做反應，實習結束前由教學負責主治醫師與學生座談，實習結束筆試時由學生線上回填學習評值表。

陸、教科書及參考書目

- 一、Fitzpatrick's Dermatology in general medicine, 9th edition, 2019, McGraw-Hill
- 二、Andrews' Diseases of the Skin: Clinical Dermatology, 12th edition, 2016, Elsevier
- 三、Fitzpatrick's Color Atlas and Synopsis of Clinical Dermatology 7th edition, 2013, McGraw-Hill
- 四、Rook's Textbook of Dermatology. 9th edition, 2017, Wiley.
- 五、McKee's Pathology of the Skin. 5th Edition, 2019, Elsevier

柒、反省與實踐（從經驗中學習）：(附件九：學習護照)

附件一

以下名單為112年6月起之在職人員：

皮膚部人員	
皮膚病理科	特聘專家-李玉雲教授
皮膚外科	科主任-趙曉秋副教授
皮膚光療科	科主任-王德華教授
皮膚免疫科	科主任-楊朝鈞教授
主治醫師	許釗凱副教授兼醫師 廖怡貞醫師 朱家葆醫師 杜威廷醫師 何英右醫師 李兆甯醫師 劉威廷醫師
住院醫師	
	R4 陳萱醫師、陳麒亘醫師；2位醫師於112/8/1離職。
	R3 黃信奮醫師、林謙醫師；2位醫師於112/8/1升R4。
	R2 王瀚棠醫師、葉芮苒醫師；2位醫師於112/8/1升R3。
	R1 曾怡倫醫師、賴奕慈醫師；2位醫師於112/8/1升R2。
	侯秉宸醫師、張藝瀚醫師；2位醫師於112/8/1為新進R1。
兼任主治醫師 (依筆劃排序)	教學：王正坤醫師、林宏謙醫師、林旻憲醫師、 許明隆醫師、黃靖媛醫師、劉貴中醫師 門診：許明隆醫師
皮膚部辦公室(醫學院6F 82-0621室) 秘書：王小姐 電話：(06)2353535分機5417 傳真：(06)2766180 Email： em75417@ncku.edu.tw	

附件二 實習醫學生課程大綱(112年6月起調整如下)

教師	主題
VS李玉雲(58001)	病例教學討論Case discussion
VS趙曉秋(58002)	①皮膚外科(Skin surgery) ②皮膚腫瘤(Cutaneous neoplasms)
VS王德華(58005)	①光治療學 (phototherapy) ②白斑(vitiligo)
VS楊朝鈞(58003)	毛髮疾病(Hair diseases)
VS許釗凱(58020)	①皮膚病理及病例討論(Dermatopathology) ②水泡性皮膚病(Blistering disorder)
VS廖怡貞(58025)	乾癬(Psoriasis)
VS朱家葆(58004)	①系統性疾病之皮膚表現 (Systemic disease-related skin presentation)
VS杜威廷(58007)	學習目標、課程介紹及評量方法 導談及學習意見回饋 藥物疹 (Approach to drug eruptions) 指甲疾病 (Nail diseases)
VS何英右(58012)	嬰幼兒及孕婦常見皮膚變化與疾病 (Infancy and Pregnancy Dermatoses)
VS李兆甯(58009)	癌症免疫療法與標靶藥物之皮膚副作用(Skin Reactions to Targeted Therapy and Immunotherapy)
VS劉威廷(58008)	異位性皮膚炎 (Atopic dermatitis)
總醫師	①Clerkship Orientation ②皮膚科常用藥物概論(Dermatology Drugs)
兼任VS許明隆	感染性皮膚病(Infection)
兼任VS黃靖媛	青春痘(Acne)
兼任VS王正坤	皮膚美容醫學(Cosmetic dermatology)
兼任VS林旻憲	Five skin diseases you must know for non-dermatologist's inpatient care
PS：如有教師出國研究，課程另作調整。	

Admission Note (全院範例)

Basic Information

Name: Mr.XX

Age: 70 year-old man

Admission Date: 2004/10/16

Chart No.: 00692762

Chief complaint

Dizziness and dyspnea on exertion in recent 10 days

Present illness

This 70 year-old gentleman has had hypertrophic obstructive cardiomyopathy (HOCM) and hypertension for more than ten years. He has regular follow-ups at 蘇文政診所. He takes care of all his daily activities. He is sometimes short of breath when walking a long distance. Neither orthopnea nor paroxysmal nocturnal dyspnea was complained.

Ten days ago, he felt dizziness, general discomfort and shortness of breath after walking uphill. No chest discomfort, palpitation or cold sweating was associated. This resolved after taking a rest. No other discomfort was noted afterwards.

However, this happened again when he walked to lunch on 10/16. Near-syncope sensation brought him to our ER.

Past history

- Hypertrophic obstructive cardiomyopathy x 10 years
- Hypertension(+): under medical control x 10 years
- Bilateral femoral head AVN s/p operation dated?
- Gastric and duodenal ulcer history x duration?
- Asthma in childhood
- HCV infection dated?

Current medications (例)

- Verapamil(Isoptin) (240 mg) 1# po qd
- Isosorbide dinitrate(Isordil) (10 mg) 1# po qd
- Atenolol(Tenormin) (50 mg) ¼# po qd since 9/20
- Magnesium oxide(MgO) (250 mg) 1# po qd
- Celecoxib(Celebrex) (200 mg) 1# po bid
- Chlorzoxazone(Solaxin) (200 mg) 1# po bid
- Hydrotalcite(Nacid) (500 mg) 1# po bid
- Lansoprazole(Takepron) (30 mg) 1# po qd

Social history

- Smoking (+): ¼ pack/day > 30 years, quit for 2 months
- Alcohol drinking (-)
- Occupation: retired engineer

Family history

His mother had hypertension and heart disease (uncertain). No mention of siblings. No history of sudden death. (需畫三代家族史)

Review of systems

- **General**
 - Malaise(+), Fever(-), Body weight loss(-), **dizziness(+)**
- **Cardiovascular**
 - Chest tightness(-), pressure (-), **dyspnea on exertion(+)**
 - Lie flat or use pillows, orthopnea (-)
 - Noticed heart racing, aware of heartbeat (-)
 - Ankle swelling (-), Cold hands, feet (-)
- **Pulmonary**
 - Cough(-), blood (-), wheeze (-), night sweats (-)
- **Alimentary**
 - Weight gain (-), poor appetite (-)
 - Abdominal pain or discomfort (-), Bloating, distention (-)
 - Nausea (-), vomiting (-), Bowel habits change (-)
 - Incontinence (-), constipation(-), diarrhea (-)
 - Stool color: yellow, blood (-), consistency: normal
- **Genitourinary**
 - Frequency (-), dysuria (-), nocturia (-), Genitourinary pain, discomfort (-)
 - Urine color change (-)
- **Skeletal**
 - R't hip pain(+), ROM: no limitation

Physical examination

- Consciousness: clear, well oriented
- Appearance: ill-looking
- Vital Sign: T 35.7, P 60/min, regular, B.P. 98/42, RR 16/min
- HEENT: Sclera: not icteric, Conjunctiva: not pale

Oral cavity & throat: intact, not injected

Neck: Supple, no palpable mass, JVE(-); rapid upstroke, no bruits

- Chest: Markedly increase in AP diameter. Symmetric expansion, prolonged expiratory phase, no crackles
- Heart:

PMI: in 5th intercostal space of ant. axillary line

Heave LV(+)

Grade III/VI systolic murmur over apex, radiates to axilla

Grade III/VI systolic murmur over LUSB, RUSB, accentuated by the Valsalva maneuver. No radiation to the carotids.

■ Abdomen: Soft and flat, Bowel Sounds: normoactive

No tenderness or rebound pain

Liver and spleen: no enlargement

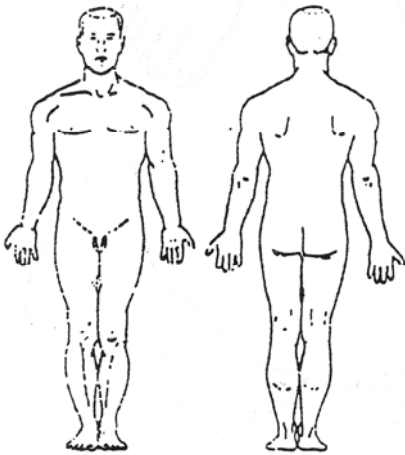
■ Extremities: no pitting edema

Pulsation: FA PA Dorsalis

R't ++ + ++

L't ++ + ++

Cutaneous Findings



ECG 10/16 at ER

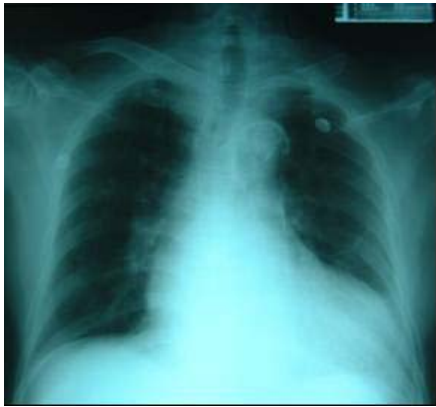Junctional rhythm with junctional echo beats (or APC).

No visible sinus activity.

Sinus bradycardia 50/min (post atropine 1 mg I.V.)

LVH, slow R wave progression V₁-V₃

CXR 10/16 at ER



Severe cardiomegaly
Calcified aortic knob
And thoracic aortic wall
Tortuous aorta
LA enlargement
No CHF

Lab data

CBC/DC at ER

WBC	Hb	Hct	MCV	MCH
3800/cmm	9.9 g/dl	30.8%	71.6fl	23.1pg

MCHC	RDW	Plt
32.3g/dl	23.6%	181K/cmm

Seg	Eos	Baso	Mono	Lymph
61%	6%	0%	7%	26%

Biochemistry

Cr	BUN	GOT	GPT
1.4	22	36	30

Na	K	Digoxin
142	4.1	0.7

Other Diagnostic Tests:

Cardiac Echo 10/18

- Septal hypertrophy
- Adequate LV systolic function (EF: 72.7%)
- LVOT obstruction (PG: 118 mmHG)
- Severe eccentric posterior MR

Tentative diagnosis

- Sinus nodal dysfunction (sick sinus syndrome) intrinsic, exacerbated by drug therapy.
- Hypertrophic obstructive cardiomyopathy
- Hypertension by history
- Chronic obstructive pulmonary disease (COPS)
- Anemia (hypochromic, hypocytic) etiology to be determined

Problem Lists

Use SOAP note

Admission Note (皮膚科範例)

Basic Information

Name: XXX

Age: 32 year-old woman

Admission Date: 2005/03/16

Chart No.: 00692XXX

Chief complaint

Generalized itchy skin rash for 1 year with recent exacerbation for 3 days.

Present illness

This 31 year-old woman, G2P2, had progressive itchy generalized skin rash on the four extremities during her second pregnancy 1 year ago. The excoriated, weeping plaques are predominantly on the four extremities. Sparse lesion developed on the abdomen and face. No photosensitivity, seasonal change, fever or oral ulcer was noted. No travel history could be traced. She didn't take any medicine other than Chinese herbal medicine and antihistamine intermittently. She didn't use any new detergents, chemicals or cosmetics recently. She didn't raise any pets.

She was admitted to our hospital last August and atopic dermatitis was diagnosed with elevated IgE (1707) and positive MAST to mites (4+). During the last 7 months, she had follow-up at our clinic and local medical clinics with fair control of the disease. However, worsening of the skin lesion was noted 3 days ago.

Past history

1. DM(-), HTN(-)
2. Allergic rhinitis(+), Asthma(-)
3. HBV carrier(+) diagnosed for 20 years
4. Lymphedema s/p lymphadectomy, left lower leg 10 years ago
5. Drug allergy(-)
6. Family history: not contributory

Current medications

- Hydroxyzine pamoate(Vistaril) (25 mg) 1# po qid
- Prednisolone(Prednisolone) (5 mg) 2# po tid
- Triam-P ointment(Triamcinolone 0.1% oint) topical use, bid

Social history

- Smoking (+): ¼ pack/day > 3 years, quit for 2 years
- Alcohol drinking (-)
- Occupation: housewife

Family history

Her parents do not have atopic disease. (需畫三代家族史)

Review of systems

■ **General**

- Malaise(-), Fever(-), Body weight loss(-), dizziness(-)

■ **Cardiovascular**

- Chest tightness(-), pressure (-), dyspnea on exertion(-)
- Lie flat or use pillows, orthopnea (-)
- Noticed heart racing, aware of heartbeat (-)
- Ankle swelling (-), Cold hands, feet (-)

■ **Pulmonary**

- Cough(-), blood (-), wheeze (-), night sweats (-)

■ **Alimentary**

- Weight gain (-), poor appetite (-)
- Abdominal pain or discomfort (-), Bloating, distention (-)
- Nausea (-), vomiting (-), Bowel habits change (-)
- Incontinence (-), constipation(-), diarrhea (-)
- Stool color: yellow, blood (-) ,consistency: normal

■ **Genitourinary**

- Frequency (-), dysuria (-), nocturia (-), Genitourinary pain, discomfort (-)
- Urine color change (-)

■ **Skeletal**

- ROM: no limitation

Physical examination

- Consciousness: clear, well oriented
- Appearance: ill-looking
- Vital Sign: T 35.7, P 60/min, regular, B.P. 98/42, RR 16/min
- HEENT: Sclera: not icteric, Conjunctiva: not pale

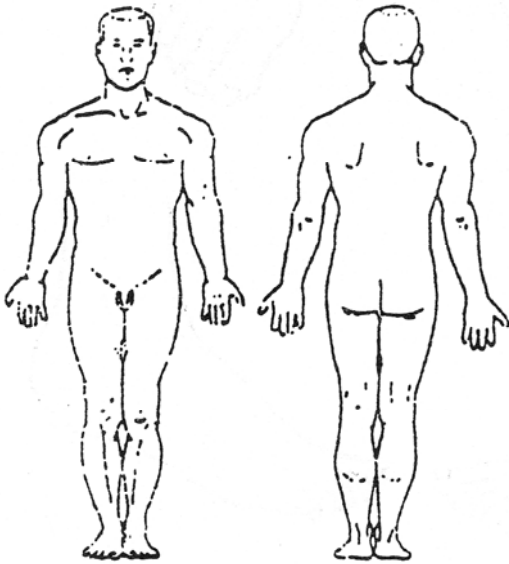
Oral cavity & throat: intact, not injected

Neck: Supple, no palpable mass, JVE(-); rapid upstroke, no bruits

- Chest: Markedly increase in AP diameter. Symmetric expansion, prolonged expiratory phase, no crackles
- Heart: Regular heart beat, no murmur
- Abdomen: Soft and flat, Bowel Sounds: normoactive
 - No tenderness or rebound pain
 - Liver and spleen: no enlargement
- Extremities: no pitting edema

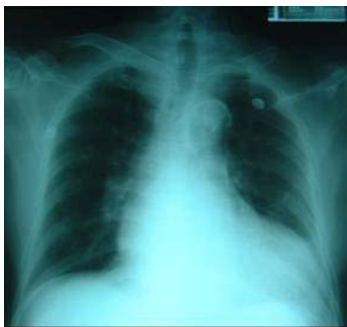Cutaneous Findings

1. Diffuse, generalized, excoriated and crusted, erythematous plaques and papules predominantly on the four extremities. Sparse lesions are located on the trunk, face and neck. Some plaques are oozing, weeping and eroded.
2. Diffuse, brownish, indurated and verrucous plaques on the left lower extremity with focal erosions.



ECG(3/16): Normal sinus rhythm

CXR(3/16)



Severe cardiomegaly
 Calcified aortic knob
 And thoracic aortic wall
 Tortuous aorta
 LA enlargement
 No CHF

Lab data

CBC/DC(3/15)

WBC	Hb	Hct	MCV	MCH
3800/cmm	9.9 g/dl	30.8%	71.6fl	23.1pg

MCHC	RDW	Plt
32.3g/dl	23.6%	181K/cmm

Seg	Eos	Baso	Mono	Lymph
-----	-----	------	------	-------

61% 6% 0% 7% 26%

Biochemistry(3/15)

Cr	BUN	GOT	GPT
1.4	22	36	30

Na	K
142	4.1

IgE	MAST
1707	Mite 4+

Other Diagnostic Tests:

KOH exam on 10/18

- No fungus was detected

Problem list (Tentative diagnosis)

- Atopic dermatitis, generalized, exacerbated
- Elephantiasis verrucosa nostras, right leg

Assessment and plan for each problem

Use problem-oriented medical record (POMR) format

Progress Note

問題導向病情記錄 (Problem-oriented medical record)

在完成General History 時已知病人有那些問題，並一一記錄在Problem-oriented Sheet 之上。而在住院期間，每日得到的新資料 (包括新的症狀及新的檢查發現) 須加以思考與那些問題有關，或是新的問題。按照SOAP (subjective findings、objective findings、assessment 及plans) 的順序來記載。

Progress note

Modified POMR (S. O. A and P)

S: subjective

O: objective

A: assessment

P: plan

Problem 1:

A: assessment(不是寫診斷,而是寫今天此問題之診斷治療進展如何, 變好?變壞?
或有新的確定診斷..)

P: plan(包括診斷, 治療, 及衛教計劃)

Problem 2:

A: assessment

P: plan

(Modified from 薛尊仁教授上課講義)

附件五

國立成功大學醫學院附設醫院皮膚部住診教學紀錄表

基本資料(病歷號、年齡、性別)		教學時間(年、月、日、時間)		教學地點	指導教師
VS :		R :	Intern :	S.Clerk/ J.Clerk :	專科護理師 其他醫護人員 :
被 指 導 者 簽 章					
	病情概述：(被指導者填寫)				
教學主題：(請勾選此次迴診所強調的教學主題，可複選，並摘要記錄教學內容於下表) <input type="checkbox"/> 1.病史及理學檢查 <input type="checkbox"/> 2.診斷思路 <input type="checkbox"/> 3.治療及用藥 <input type="checkbox"/> 4.病歷書寫 <input type="checkbox"/> 5.醫療品質 <input type="checkbox"/> 6.醫倫法律 <input type="checkbox"/> 7.實證醫學					
教 學 內 容 精 華 摘 要	討論內容(被指導者填寫，如版面不足請記錄於背面)				
	醫倫法律或實證醫學討論摘要(被指導者填寫，如版面不足請記錄於背面)				
記錄者簽名：			指導醫師簽名：		

背面有記錄

教
學
內
容
精
華
摘
要

OSCE 教案學生表現評量

學生姓名：

學號：

評量項目	完整執行 <input type="checkbox"/> A	已嘗試 但不完整 <input type="checkbox"/> B	未嘗試 <input type="checkbox"/> C
<ol style="list-style-type: none"> 1. 會議是否在一安靜，且隱私性之場所 2. 是否開場白時自我介紹 3. 於會談早期使用開放性問句 4. 使用簡單及簡要的問句 5. 於必要時澄清病人之說法 6. 適切之眼神接觸與詢問姿態 7. 使用方法使病人多談，包含點頭、嗯或重複病人之說法 8. 會談中儘量做到不打斷病人 9. 同理心 10. 澄清適切相關的過去疾病與醫療史 11. 各症狀其發展時序之澄清，少使用醫學術語 12. 評估病人臨床病灶 13. 澄清適切相關之家族史及職業 <ol style="list-style-type: none"> a. 養寵物與否? b. 其他家人也有類似情形? c. 從事何種工作? 14. 可以在門診做那些檢查來確立診斷 <ol style="list-style-type: none"> a. KOH b. Wood's light 15. 請學生陳述其鑑別診斷及單一最可能診斷 <ol style="list-style-type: none"> a. Tinea capitis b. Cellulitis c. Pediculosis capitis 16. 建議之處理 <ol style="list-style-type: none"> a. 投與抗黴菌藥 b. 適合的 shampoo 17. 總評 			

技術評量

KOH 檢查

- a.請病人到 KOH 檢查間
- b.請病人露出病灶處
- c.用酒精消毒刮刀
- d.以紙巾把刮刀擦乾
- e.與病人解釋取檢體有些不舒服
- f.取檢體的方式正確與否?
 - i.頭髮取 black dot 或斷髮外，以不施力即可夾取者為佳
 - ii.身上皮膚：取紅疹邊緣(active margin 處)
 - iii.指甲取指甲下方的屑屑
 - iv.懷疑 scabies，取手指縫或手腕或手肘有 burrow 處
 - v.以酒精消毒刮刀且用紙巾擦乾
- g.以顯微鏡觀察
 - i.顯微鏡本身的清潔與否
 - ii.condensor 要調低
 - iii.燈光亮度不要太亮
 - iv.觀察檢體，有時需要時間以溶解皮膚
- h.關燈，清理玻片及顯微鏡
- i.詳細在病歷上記錄結果
- j.寫上初步診斷
- k.與主治醫師討論
- l.與主治醫師一起向病人解釋
- m.請病人在診間外面稍待

Tzanck smear

1. 請病人到 KOH 檢查間
2. 請病人露出病灶處
3. 與病人解釋步驟及取檢體時有些不舒服
4. 輕輕地以針頭或刀片將水泡刺破
5. 輕輕地以針頭或刀片刮取水泡底部及水泡頂部
6. 將刮取物抹片於乾淨的載玻片上
7. 使檢體風乾
8. 以紗布將病人傷口覆蓋
9. 檢體染 Liu's stain
10. 以顯微鏡觀察
 - ①. 單純皰疹、帶狀泡疹：觀察有無 multinucleated giant cells
 - ②. 天皰瘡：觀察 acantholytic cells
11. 關燈，清理玻片及顯微鏡
12. 詳細在病歷上記錄結果
13. 寫上初步診斷
14. 與主治醫師討論
15. 與主治醫師一起向病人解釋
16. 請病人在診間外面等候

成功大學醫學院附設醫院教學病歷紀錄表(續：第 頁)

()門診 ()住院醫師
 (✓)住診 (✓)實(見)醫師

指導老師 李玉雲教授 被指導者 _____ 科別 皮膚科 日期 _____

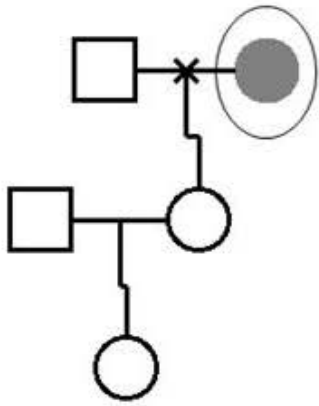
病患基本資料(病歷號：16209xxx) Student portrait here

姓名：鍾 XX 職業：無

性別：XX 婚姻狀況：離婚

年齡：XX 籍貫：台灣-福佬人

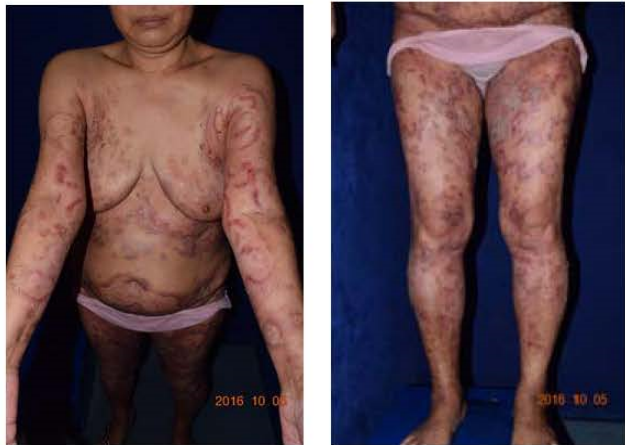教學內容	指導老師修正意見
<p>主要診斷： Type I ulceration induced by methotrexate</p> <p>次要診斷： Psoriasis vulgaris with pustular formation Psoriatic arthritis.</p> <p>1. 病史：</p> <p>Chief complaint: Numerous progressive painful annular erosions and ulceration over trunk and four extremities for about two to three weeks</p> <p>Present illness: This is a 55-year-old female who had a history of (1). Psoriasis vulgaris with pustular formation. (2). Psoriatic arthritis. (3). HCV infection. (4). hypertension. She received regular OPD follow-ups in our OPD for psoriasis vulgaris, local clinic for HTN and GI OPD in Tainan Municipal Hospital for HCV infection. This time, she has progressive painful erosions and ulceration over trunk and four extremities for about three weeks. She had phototherapy (ubUVB) during 2014/04/11 to 2014/10/27, Acitretin during 2014/06/30 to 2015/06/26 and cyclosporine during 2015/06/26 to 2016/08/24. Lab showed renal impairment on 8/25, so we changed to Methotrexate since 2016/09/16. There was previous Methotrexate induced decreased WBC, so we pay close attention to the side effect by Methotrexate this time. However, new itchy pustules appeared over bilateral axillary area was noted in one week after Methotrexate started. In our OPD on 2016/10/05, there are numerous progressive painful erosions and ulceration on violaceous psoriasis lesions base over her trunk and extremities, which made it hard to fall asleep even under the pain management of Traceton 1# TID. She denied N/V, GI discomforts, decreased urine output or fever after the use of MTX. We decided to discontinued Methotrexate due to skin ulceration and elevated liver enzymes (AST/ALT 71/130 u/l). Lab didn't show hematologic abnormality, and renal function still went worse this time. Due to the extended wound, she was then admitted with the diagnosis skin ulceration induced by Methotrexate, type I reaction, for further management and survey.</p>	

Past history:	
HCV infection.	
Hypertension.	
Social history:	
Smoking : 無	
Drinking : 無	
Betel nut : 無	
Drug abuse : 無	
教育程度 : 高中/職	
宗教背景 : 道教	
Family history:	
	
Current medication:	
[Diclofenac SR 緩釋 75mg/tab (Voltaren)] 1 tab BIDPC PO	
[Fexofenadine 60mg/tab (Allegra)] 1 tab BIDPC PO	
[Hydroxyzine 25mg/cap (Vistaril)] 1 cap QID PO	
[Folic Acid tab 5mg/tab(Folic Acid)]1 tab QW PO	
[Methotrexate tab 2.5mg/tab(Methotrexate)] 4.00 tab QW PO	
[Predonine 5mg/tab(Prednisolone)] 2.00 tab BID PC PO	
[Sirin 1# tid] TID[自備藥]	
[Ranitidine 1# bid] BID[自備藥]	
[Propranolol 10mg 1# bid] BID[自備藥]	
[Amlodipine 5mg 1# qd] QD[自備藥]	
[Losartan 50mg 1# qd] QD[自備藥]	
[lorazepam 1mg hs] HS[自備藥]	
2. 理學檢查 : (Pertinent results)	
Vital Signs: T: 36.8°C(10/05 19:05); P: 78/min(10/05 19:05) R: 18/min(10/05 19:05); BP: 148/90mmHg(10/05 19:05) 【 Consciousness 】 : clear 【 Sclera 】 : not icteric	

【Conjunctiva】 : not injected, not pale
【Oral/throat】 : not injected, not dry
【Neck】 : stiffness(-), LAP (-)
【Chest】 : normal BS
【Heart】 : RHB, no murmur
【Abdomen】 : soft, tenderness (-), normoactive bowel sound
【Limbs】 : warm, no edema
【Peripheral pulse】 : symmetric and active
【Skin】 : numerous annular erosions and oozing ulceration on the violaceous annular psoriasis lesions base over her extremities and trunk.
 Mucosal ulceration (-).
 Geographic tongue (-)

Cutaneous finding: (Include figure)

- numerous annular erosions and oozing ulceration on the violaceous annular psoriasis lesions base over her extremities and trunk




3. 實驗室檢驗：(Pertinent lab data)

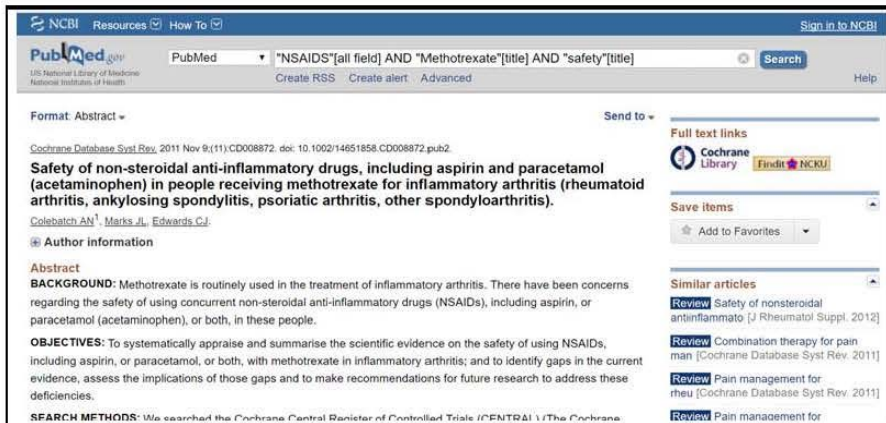
Lab data			一般 (緊急) 血液檢驗報告	
檢驗名稱	血液	血液	檢驗名稱	血液
常規 (緊急) 生化檢驗報告			檢驗名稱	2016-10-05
(單位)			(單位)	15:59
檢驗名稱	2016-10-05	2016-10-05	WBC(10 ³ /μL)	10.7(H)
(單位)	19:47	16:31	RBC(10 ⁶ /μL)	4.11
BUN(mg/dL)		23(H)	Hb(g/dL)	11.6
CREA(mg/dL)		1.20(H)	Hct(%)	36.0
eGFR		47(L)	MCV(fl)	87.6
AST(U/L)		71(H)	MCH(pg)	28.3
ALT(U/L)		130(H)	MCHC(g/dL)	32.3(L)
CRP(mg/L)	<7.0		RDW(%)	15.6(H)
			Plt(10 ³ /μL)	208
			MPV(fl)	7.0

4. 影像檢查：(Pertinent image data)



5.診斷：	
<p>ulceration secondary to MTX treatment is an exclusion diagnosis; a temporal relation with initiation, increase of the dose or concomitant therapies must be considered.</p> <p>Reference: European Journal of Dermatology, 2001 Sep-Oct;11(5):450-2, Cutaneous ulceration as a sign of methotrexate toxicity.</p>	
6.鑑別診斷：	
<p>1) flare of psoriasis or an acute episode of pustular psoriasis</p>  <p>這 case 在診斷的部分有兩個重點</p> <ol style="list-style-type: none"> 1) Underlying psoriasis vulgaris 2) New onset of the use of MTX <p>- 在 9/21 時 cutaneous finding : erythematous patches and pustules over trunk and extremities , 這樣的情形的確無法正確區分, 但跟以往不同的是 painful lesions , 也許是一個 hint</p> <p>10/5 時明顯產生 extensive ulceration and erosion 診斷就明確和 flare of psoriasis 區分開來了</p> <p>- 也因為綜合 1+2 , 並不會優先考慮 vasculitis, antiphospholipid-antibody syndrome, infectious ulceration, pyoderma gangrenosum 等等也會產生 ulceration lesions 的 DDX</p> <p>2) Stevens Johnson Syndrome / Toxic Epidermal Necrolysis</p> <p>若從 lesion 的型態切入, 此 DDX 應該是不用列入, 但 MTX 的確也可能引發 skin necrosis</p> <p>Reference: Journal of the American Academy of Dermatology Volume 36, Issue 5, Supplement, May 1997, Pages 815–818, Methotrexate-induced toxic epidermal necrolysis in a patient with psoriasis.</p>	
7.藥物治療：	
<ol style="list-style-type: none"> a. Discontinued MTX b. Ciprofloxacin 250mg/tab (Ciproxin)] 2 tab BIDAC PO c. Wound care : Gentamicin oph oint 眼膏 0.3% 5g/tube (Gentamycin) d. Pain control: [Tramadol 低 50mg/cap (Tramtor)] 1 cap Q6H PO e. [Diclofenac SR 緩釋 75mg/tab (Voltaren)] 1 tab BIDPC PO [Fexofenadine 60mg/tab (Allegra)] 1 tab BIDPC PO [Hydroxyzine 25mg/cap (Vistaril)] 1 cap QID PO 	
8.其他治療及預防計劃：	
HTN and HCV : keep current medication	

<p>Psoriasis treatment plan: Acitretin 10mg/cap (Neotigason)]1 cap QD or consider biological agents 生物製劑健保給付標準 參考全民健康保險藥品給付規定-103 年版第八節 8. 2. 4. 6.</p>																												
<p>9.醫病關係之建立及會談、溝通技巧</p>																												
<p>乾癬是一個長期的疾病，在治療上也是長期抗戰，此病人在原本乾癬治療 course 上反覆復發，也使用過各式各樣的治療，如何建立同理病人並建立病人對治療的信心是很重要的課題，釐清並明確記錄病人變化，以便能更掌握病人對藥物的反應是需要努力的地方。</p>																												
<p>10.此例值得討論的重點以及 specific questions</p>																												
<p>*使用 MTX 而產生 adverse effect 的 risk factor 有 advanced age, renal impairment, the absence of folate supplementation, drug interactions, and medication errors. 而在 drug interaction guideline 參考如下 * Medications that may increase methotrexate toxicity</p>																												
<table border="1"> <thead> <tr> <th>NSAIDs</th> <th>Antibiotics</th> <th>Others</th> </tr> </thead> <tbody> <tr> <td>Salicylates</td> <td>Trimethoprim/sulfamethoxazole</td> <td>Barbiturates</td> </tr> <tr> <td>Naproxen</td> <td>Sulfonamides</td> <td>Colchicine</td> </tr> <tr> <td>Ibuprofen</td> <td>Penicillins</td> <td>Dipyridamole</td> </tr> <tr> <td>Indomethacin</td> <td>Minocycline</td> <td>Ethanol</td> </tr> <tr> <td>Phenylbutazone</td> <td>Ciprofloxacin</td> <td>Phenytoin</td> </tr> <tr> <td></td> <td></td> <td>Sulfonylureas</td> </tr> <tr> <td></td> <td></td> <td>Furosemide</td> </tr> <tr> <td></td> <td></td> <td>Thiazide-diuretics</td> </tr> </tbody> </table>	NSAIDs	Antibiotics	Others	Salicylates	Trimethoprim/sulfamethoxazole	Barbiturates	Naproxen	Sulfonamides	Colchicine	Ibuprofen	Penicillins	Dipyridamole	Indomethacin	Minocycline	Ethanol	Phenylbutazone	Ciprofloxacin	Phenytoin			Sulfonylureas			Furosemide			Thiazide-diuretics	
NSAIDs	Antibiotics	Others																										
Salicylates	Trimethoprim/sulfamethoxazole	Barbiturates																										
Naproxen	Sulfonamides	Colchicine																										
Ibuprofen	Penicillins	Dipyridamole																										
Indomethacin	Minocycline	Ethanol																										
Phenylbutazone	Ciprofloxacin	Phenytoin																										
		Sulfonylureas																										
		Furosemide																										
		Thiazide-diuretics																										
<p>Reference: Guidelines of care for the management of psoriasis and psoriatic arthritis : Section 4. Guidelines of care for the management and treatment of psoriasis with traditional systemic agents 而我的病人並沒有合併使用上表列出的藥物，我想更清楚了解使用 MTX 的病人合併使用 NSAIDs 的安全性 (1) 提出問題: P: patient using MTX treatment I: use of non-steroidal anti-inflammatory drugs C: free from the use of NSAIDs O: adverse effect (2) 搜尋 paper: Database: Pubmed 關鍵字: "NSAIDS"AND"Methotrexate"AND"safety" 結果: 41 篇 paper，閱讀 abstract 後覺得不 specific 修正搜尋關鍵字 "NSAIDS"[title] AND "Methotrexate"[title] AND "safety"[title] 而不到結果，又修正成"NSAIDS"[all field] AND "Methotrexate"[title] AND "safety"[title] 找到一篇 Conchrane 的 review</p>																												



NCBI Resources How To Sign in to NCBI

PubMed "NSAIDS[all field] AND Methotrexate[title] AND safety[title] Search

Format: Abstract Send to

Cochrane Database Syst Rev. 2011 Nov 9;(11):CD008872. doi: 10.1002/14651858.CD008872.pub2

Safety of non-steroidal anti-inflammatory drugs, including aspirin and paracetamol (acetaminophen) in people receiving methotrexate for inflammatory arthritis (rheumatoid arthritis, ankylosing spondylitis, psoriatic arthritis, other spondyloarthritis).

Colebatch AN¹, Marks JL, Edwards CJ.

Author information

Abstract

BACKGROUND: Methotrexate is routinely used in the treatment of inflammatory arthritis. There have been concerns regarding the safety of using concurrent non-steroidal anti-inflammatory drugs (NSAIDs), including aspirin, or paracetamol (acetaminophen), or both, in these people.

OBJECTIVES: To systematically appraise and summarise the scientific evidence on the safety of using NSAIDs, including aspirin, or paracetamol, or both, with methotrexate in inflammatory arthritis; and to identify gaps in the current evidence, assess the implications of those gaps and to make recommendations for future research to address these deficiencies.

SEARCH METHODS: We searched the Cochrane Central Register of Controlled Trials (CENTRAL) (The Cochrane

Full text links
Cochrane Library Findit! NCRJ

Save items
Add to Favorites

Similar articles
Review Safety of nonsteroidal antiinflammato [J Rheumatol Suppl. 2012]
Review Combination therapy for pain man [Cochrane Database Syst Rev. 2011]
Review Pain management for rheu [Cochrane Database Syst Rev. 2011]
Review Pain management for

(3) 文章內容評讀:

Background: Methotrexate is routinely used in the treatment of inflammatory arthritis. There have been concerns regarding the safety of using concurrent non-steroidal anti-inflammatory drugs (NSAIDs), including aspirin, or paracetamol (acetaminophen), or both, in these people.

Objectives

To systematically appraise and summarise the scientific evidence on the safety of using NSAIDs, including aspirin, or paracetamol, or both, with methotrexate in inflammatory arthritis; and to identify gaps in the current evidence, assess the implications of those gaps and to make recommendations for future research to address these deficiencies.

Search methods

We searched the Cochrane Central Register of Controlled Trials (CENTRAL) (The Cochrane Library, second quarter 2010); MEDLINE (from 1950); EMBASE (from 1980); the Cochrane Database of Systematic Reviews (CDSR) and the Database of Abstracts of Reviews of Effects (DARE). We also handsearched the conference proceedings for the American College of Rheumatology (ACR) and European League against Rheumatism (EULAR) (2008 to 2009) and checked the websites of regulatory agencies for reported adverse events, labels and warnings.

Selection criteria

Randomised controlled trials and non-randomised studies comparing the safety of methotrexate alone to methotrexate with concurrent NSAIDs, including aspirin, or paracetamol, or both, in people with inflammatory arthritis.

Data collection and analysis

Two authors independently assessed the search results, extracted data and assessed the risk of bias of the included studies.

Main results

SUMMARY OF FINDINGS FOR THE MAIN COMPARISON [Explanation]

NSAIDs including aspirin or paracetamol for patients with inflammatory arthritis on methotrexate						
Patient or population: patients with inflammatory arthritis on methotrexate						
Settings:						
Intervention: NSAIDs including aspirin or paracetamol						
Outcomes	Illustrative comparative risks* (95% CI)		Relative effect (95% CI)	No of Participants (studies)	Quality of the evidence (GRADE)	Comments
	Assumed risk	Corresponding risk				
	Control	NSAIDs including aspirin and/or paracetamol				
Pulmonary Methotrexate pneumonitis Follow-up: 8 years	See comment	See comment	Not estimable	27 (2 studies)	⊕⊕⊕○ moderate ¹	No significant increase of methotrexate pneumonitis seen in those on NSAIDs or aspirin
Hepatic Liver histology/hepatic enzyme abnormalities ² Follow-up: 3.5 years	See comment	See comment	Not estimable	272 (2 studies)	⊕⊕○○ low ³	No effect in 1 study, significant increase in serum transaminases with concurrent methotrexate and aspirin in second study
Renal Glomerular and tubular injury Follow-up: 24-52 weeks	See comment	See comment	Not estimable	30 (2 studies)	⊕⊕○○ low ⁴	Svensden 2005: partly reversible adverse effect on renal function with concurrent aspirin. Seidman 1993: No increased renal toxicity with additional NSAIDs
Haematological Thrombocytopenia	See comment	See comment	Not estimable	0 (1 study)	⊕⊕⊕○ moderate ⁵	Significant correlation seen between thrombocytopenia on the day of administration of the weekly dosage of methotrexate with combined NSAID use (r = 0.6, P value < 0.05) ⁶
Withdrawal due to adverse events Methotrexate discontinuation Follow-up: 6-180 months	See comment	See comment	Not estimable	632 (3 studies)	⊕⊕○○ low ⁷	No significant association seen between methotrexate withdrawal and concurrent use of NSAIDs ⁸
All adverse events Follow-up: 8-23 days	See comment	See comment	Not estimable	283 (7 studies)	⊕⊕⊕○ moderate ⁹	There was no significant association between adverse events and concurrent use of NSAIDs

*The basis for the assumed risk (e.g. the median control group risk across studies) is provided in footnotes. The corresponding risk (and its 95% confidence interval) is based on the assumed risk in the comparison group and the relative effect of the intervention (and its 95% CI).
CI: Confidence interval;

GRADE Working Group grades of evidence
High quality: Further research is very unlikely to change our confidence in the estimate of effect.
Moderate quality: Further research is likely to have an important impact on our confidence in the estimate of effect and may change the estimate.
Low quality: Further research is very likely to have an important impact on our confidence in the estimate of effect and is likely to change the estimate.
Very low quality: We are very uncertain about the estimate.

Conclusion:

the concurrent use of NSAIDs with methotrexate appears to be safe provided appropriate monitoring is performed. The use of anti-inflammatory doses of aspirin should be avoided.

11. 此例之學習心得

此病人發生之病灶是較不常見的情形，較難透過教科書找到完整的篇章，要學會利用網路搜尋資源，並觀察 case report 之間的關聯，回推應用到病人身上；此病人另一個大議題是 psoriasis 的治療計畫，回顧 course 病人陸陸續續使用過的 systemic treatment 有 ubUVB, Acitretin, cyclosporine, Prednisolone, Methotrexate 基本上是包了所有的治療方式，然而不是有毒性副作用就是沒效果，review 健保規範時病人似乎也還無法達到使用生物製劑的程度，現階段還是要讓 ulcerations 好好復原後，觀察後續 psoriasis 的變化，而思考要如何制定接下來的計畫

成功大學醫學院附設醫院教學病歷紀錄表(續：第 頁)

()門診 ()住院醫師
 (✓)住診 (✓)實(見)醫師

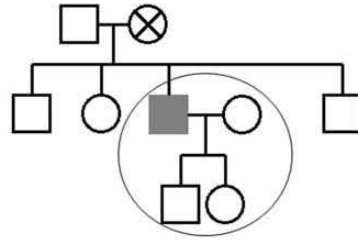
指導老師 李玉雲教授 被指導者 _____ 科別 皮膚科 日期 _____

病患基本資料(病歷號：)	Student portrait here
姓名：郭 XX	職業：電信業-工人
性別：XX	婚姻狀況：已婚
年齡：XX	籍貫：台灣-福佬人

教學內容	指導老師修正意見
主要診斷： Sweet syndrome 次要診斷：	
1. 病史：	
Chief complaint:	
Several widespread asymptomatic erythematous papules/plaques with pustules over face, trunk and four extremities for 2 weeks	
Present illness:	
<p>This is a 53 years old male who was generally healthy before. He had no underlying disease. Past history related to present illness is that he had left side cervical lymphadenopathy on last March. Initially he went to ENT at 嘉基, and the doctor suspected nasopharyngeal cancer by endoscopy. Biopsy was done at suspected nasopharyngeal lesion instead of the neck LAP, and the result showed benign lesion. PET was also suggested, but no positive finding was noted.</p> <p>This time he came to our clinic due to several painful erythematous papules/plaques with pustules over face, trunk and extremities for 2 weeks. However he actually had four periods of skin lesion burst. First period happened in last June. There were 1-2 painful erythematous firm papules or plaques on left sole, which made it hard for him to walk. He went to an orthopedics clinic for help. No any improvement after taking medication from the orthopedics doctor for 1 month, and steroid injection was then applied finally. The lesion got dramatically improved. Second period happened around last September. There were several tender itchy erythematous pustules and vesicles appeared on palms and soles (pompholyx-like) with one asymptomatic hen-egg sized violaceous plaques at left knee. He also stated that he found two to three enlarged lymph nodes on left neck with chin edema. He went to dermatologic 倪榮金's clinic for help. Oral prednisolone was then prescribed, and the lesion got improved again. Two months later, in November on 2016, tender erythematous</p>	

<p>papules and plaques with pustules at face and four extremities recurred. Fever appeared few days after. He then visited the dermatology clinic in 嘉基, and received skin biopsy on left forearm. According to the statement of the patient, no positive pathogen culture such as TB, fungus or Calymmatobacterium granulomatis. He did not know the result of histology finding. He kept taking oral prednisolone and ZnO ointment. Then the skin lesion got relieved. During this period he was also transferred to infection clinic in 嘉基.</p> <p>Medication for cellulitis was given, including antibiotics, Teicoplanin and Barktar, but in vain.</p> <p>The first period happened two weeks ago. Multiple erythematous to violaceous papules/plaques some with pustule formation on face, trunk, and four extremities. In addition, he complained intermittent fever, night sweating and general malaise for about 2-3 weeks. Mild nose obstruction was also complained. He went to 高醫 first, then NCKU for Dr. 李玉雲 clinic. In our clinic, his vital signs were stable, no fever or chillness was noted. Bilateral cervical lymphadenopathy were noted in physical examination.</p> <p>With the impression of sweet syndrome, pustular dermatosis of the dorsal hands, or lymphoproliferative disease, he is admitted for further survey and management.</p>	
<p>Past history:</p>	
<p>Denied</p> <p>TOCC: Travel history(-), Occupation(-), Contact history(-), Cluster(-) (2016/01/20)</p>	
<p>Social history:</p>	
<p>Smoking : 無</p> <p>Drinking : 無</p> <p>Betel nut : 無</p> <p>Drug abuse : 無</p> <p>教育程度 : 國小</p> <p>宗教背景 : 道教</p>	
<p>Family history:</p>	

- 糖尿病
- 高血壓
- 高血脂
- 冠心病
- 中風
- 慢性腎臟疾病
- 末期腎病變
- 慢性阻塞性肺疾病



Current medication:

Unclear, the patient denied, but according to the patient's statement he may use topical steroid.

2. 理學檢查：(Pertinent results)

Vital Signs:

T: 36°C(01/20 13:40); P: 98/min(01/20 13:40)

R: 18/min(01/20 13:40); BP: 140/109mmHg(01/20 13:40)

【Consciousness】 : clear

【Sclera】 : not icteric

【Conjunctiva】 : not injected, not pale

【Oral/throat】 : not injected, not dry

【Neck】 : JVE(-), stiffness(-),LAP (+) bilateral deep cervical lymph nodes(left:3cm , right:2cm), left supraclavicular node(2cm), content: rubbery to hard

【Chest】 : Inspection: symmetric expansion, no subcostal retraction

Palpation: no crepitus, No palpable axillary node

Percussion: resonance

Auscultation: normal BS

【Heart】 : Palpation: no heave, no thrill

Percussion: no increase of dullness

Auscultation: RHB, no murmur

【Abdomen】 : Inspection: globular

Palpation: soft, no organomegaly, pain (-), tenderness (-), rebound (-)

no palpable inguinal nodes

Percussion: tympanic, No shifting dullness

Auscultation: BS: normoactive

【Limbs】: pitting edema (+2), cyanosis (-), lateral weakness (-), palmar erythema (-)

【Peripheral pulse】 : symmetric and active

【NE】 :

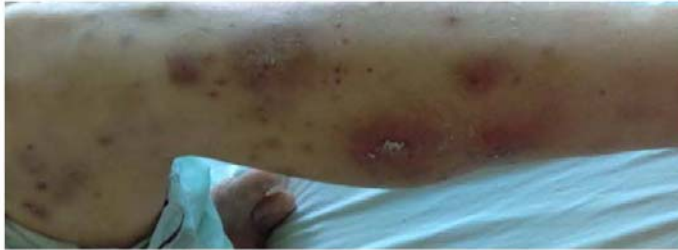Motor: RUL/LUL: 5/5, RLL/LLL: 5/5

Sensory: symmetric

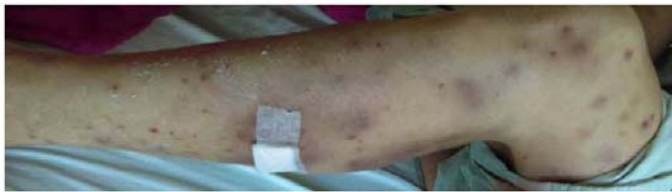Cutaneous finding: (Include figure)

- Several pinpoint to pea sized painful erythematous papules or nodules with pustule formation over face, back, four extremities
- A few violaceous, edematous plaques and nodules on the dorsal surfaces of bilateral hands
- A few hen egg-sized oval violaceous plaques over bilateral legs

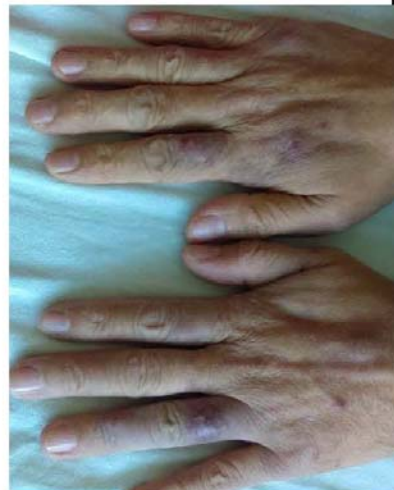BACK



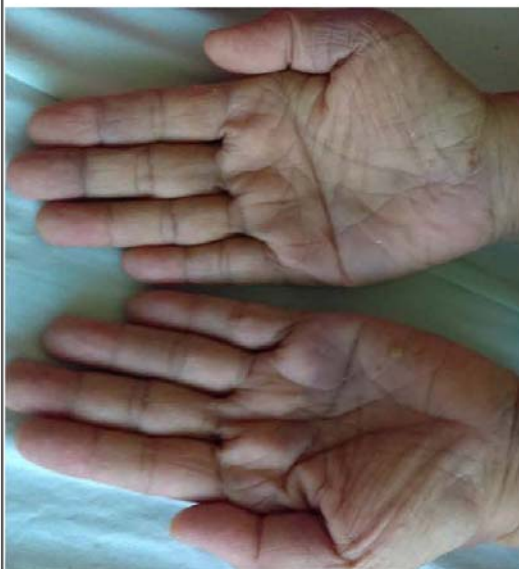LEFT LEG



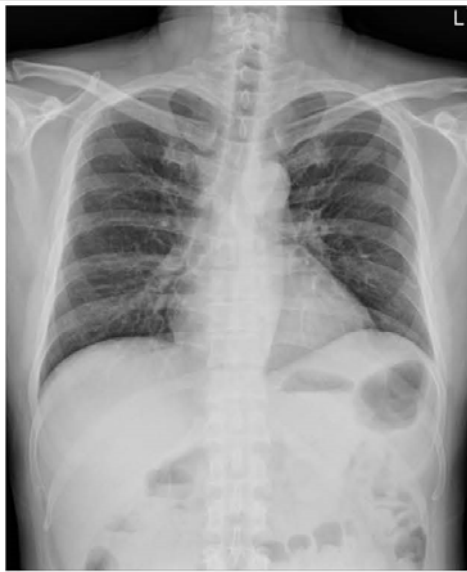LEFT LEG



DORSAL HAND



3. 實驗室檢驗：(Pertinent lab data)	
<p>2017/01/20 CBC/DC</p> <p>WBC:20400/ul, Seg(%):74, Band(%):6</p> <p>Hb:12.4g/Dl, RDW(%): 17.4 , MCV(fl):80.7</p> <p>Plt($10^3/\mu\text{L}$) 447</p> <p>BUN(mg/dL) 21</p> <p>CREA(mg/dL) 1.35</p> <p>eGFR 55</p> <p>AST(U/L) 61</p> <p>ALT(U/L) 64</p> <p>NA(mmol/L) 136</p> <p>K(mmol/L) 4.5</p> <p>-----</p> <p>LDH 734, CRP 623 (H)</p> <p>IgG(mg/dL) 3140.0, IgA(mg/dL) 479 (H)</p> <p>-----</p> <p>AST 69 U/L 10-50</p> <p>ALT 161 U/L 10-50</p> <p>Gamma-glutamyl transferase (GGT) 96 U/L (R: 10-71) (N)</p> <p>ALK-P 208 U/L (H)</p> <p>-----</p> <p>ANA(抗細胞核抗體) * 1:40(-) (N)</p> <p>RF <20 (N)</p> <p>dRVVT TEST:Negative</p> <p>Pending b2-glycoprotein and anticardiolipin</p> <p>-----</p> <p>IRON 74 ug/dL (R: 59-158)</p> <p>TIBC 255 ug/dL (R:245-419)</p> <p>Ferritin 726.0 ng/mL (R:30.0-400.0) not IDA</p> <p>-----</p> <p>01-24</p> <p>skin lesion pus culture: Acinetobacter junii</p>	
4. 影像檢查：(Pertinent image data)	



CXR:

- No active lung lesion
- No cardiomegaly
- No bony lesion

Superficial sonography:

> There are lymph nodes up to 2.5cm at bilateral necks, some are round shaped at Level I-V of bilateral necks

CT:

Multiple lymphadenopathies at bilateral necks and supraclavicular regions were noted, no other abnormal lymphadenopathy elsewhere.

5. 診斷：(需包括(1)主診斷的 criteria(2)分析並且列出重要的檢查項目，以及其結果是否支持此診斷或是缺少哪些重要的檢查)

1. Criteria (2 major + 2 minor= diagnosis)

(This patient meet 2 major+3 minor)

Major:

- (1) Abrupt onset of painful erythematous plaques or nodules
- (2) Histopathologic evidence of a dense neutrophilic infiltrate without evidence of leukocytoclastic vasculitis

Minor:

- (3) Pyrexia $>38^{\circ}\text{C}$
- (4) Association with an underlying hematologic (most commonly acute myelogenous leukemia) or visceral malignancy (most commonly carcinomas of the genitourinary organs, breast, and gastrointestinal tract), inflammatory disease (Crohn's disease and ulcerative colitis) or pregnancy, or preceded by an upper respiratory (streptococcosis) or gastrointestinal

(salmonellosis and yersiniosis) infection or vaccination

(5) Excellent response to treatment with systemic corticosteroids or potassium iodide

(6) Abnormal laboratory values at presentation (three of four):

erythrocyte sedimentation rate >20 mm/hour; positive

C-reactive protein; >8,000 leukocytes; >70% neutrophils

2. Pathology:

Biopsy I- right thigh, II- left forearm, III- left calf

Biopsy I-

(1) Follicular-centric dense infiltrate of neutrophils and eosinophils.

(2) The surface is ulcerated covered by purulent crust.

Compatible with follicular Sweet syndrome

Biopsy II-

(1) Spongiform psoriasiform hyperplasia with central small superficial ulcer.

(2) Dense neutrophilic perivascular and nodular infiltrate with nuclear dusts in the superficial and deep dermis as well as in fat lobules.

(3) Marked subepidermal edema

(4) No evidence of vasculitis.

Purpuric neutrophilic dermatitis and panniculitis, consistent with Sweet Syndrome

Biopsy III-

Consistent with the finding of biopsy II, with addition of

(1) some blood vessels in this area shows **fibrin deposit in the vessel walls** or fibrin platelet thrombi.

(2) There are no immature myeloid cells

Neutrophilic dermatitis and panniculitis with eosinophilia and thrombotic vasculopathy, suggestive of unusual Sweet syndrome

3. Lab manifestation:

(1) Peripheral leukocytosis with neutrophilia

(2) Increased CRP (623) (no ESR data)

(3) Increased platelet counts (447000/uL), maybe inflammation related

(4) IgG(mg/dL) 3140.0, IgA(mg/dL) 479

Malignancy ?

(1) Anemia (Hb=12.4) with no evidence of IDA (normal Fe and TIBC)

(2) abnormal liver function (AST 69 U/L, ALT 161 U/L)

With ALP > GGT : the lesion may be bone origin

(3) Elevated LDH :734

(4) No myelocyte/myeloblast and thrombocytopenia

Next time, consider more tumor survey:

DRE, sigmoidoscopy(>50y/o), CEA level, pap test in women,

breast, ovary, and pelvic examination in women

prostate and testicle examination in men.

6. 鑑別診斷：(請列出重要的鑑別診斷疾病以及鑑別診斷的重點)	
<p>1. pyoderma gangrenosum : Pyoderma gangrenosum (PG) is a rare inflammatory disease of unknown etiology characterized by sterile neutrophilic infiltration of the skin.</p> <p>2. Erythema nodosum : Panniculitis that has been reported in association with infections, drugs, malignancy, sarcoidosis and inflammatory bowel disease</p> <p>3. Nodular vasculitis: EI is an inflammatory panniculitis, most commonly presenting with ulcerated nodules on the calves, and frequently associated with MTB infection.</p> <p>4. halogenoderma : Halogenodermas are skin eruptions that result after exposure to halogen-containing drugs or substances.</p> <p>5. Leukemia cutis: It is the infiltration of neoplastic leukocytes or their precursors into the skin resulting in clinically identifiable cutaneous lesions.</p> <p>@ skin lesions:</p> <p>1. Pyoderma gangrenosum :</p> <ul style="list-style-type: none"> ✓ Lesions can be classified as (1) ulcerative, (2) bullous, (3) pustular, or (4) vegetative. Especially clinical (and to an extent histologic) manifestation of <u>bullous type overlap with the sweat syndrome</u> ✓ Bullous PG: painful, rapidly expanding superficial inflammatory blister that quickly erodes. Site: often appears on the upper limbs <p>2. Erythema nodosum :</p> <ul style="list-style-type: none"> ✓ Site: most on anterior lower legs, bilateral but not symmetric Also occur on knees and arms, <u>rarely on face and neck</u> ✓ Skin: indurated, very tender nodules/plaques (3-20cm), not sharply marginated (look erythema but feel like nodules). Purple-like hue to a bruise like pigmentation if hemorrhage is present. Never ulcerate and heal w/o scarring. <p>3. Nodular vasculitis:</p> <ul style="list-style-type: none"> ✓ Site: common on calves, but also on anterolateral legs, feet, and thighs; rarely elsewhere ✓ Skin: Initially erythematous, tender, or asymptomatic subcutaneous nodules or plaques. Fluctuate before ulcerating. Varicose veins are also seen on calf. <p>4. Halogenoderma :</p> <ul style="list-style-type: none"> ✓ Site: iododerma: face, mucous membrane, trunk Bromoderma: especially legs ✓ pustules or vegetating plaques; sometimes, plaques with a periphery of pustules appear <p>5. Leukemia cutis:</p> <ul style="list-style-type: none"> ✓ Skin involvement may be general or localized to one region ✓ The skin lesion present as papules, plaques, or nodules ranging from 	

violaceous to red-brown in color.

- ✓ Indurated plaques, hemorrhagic plaques, perifollicular acneiform papules, macules, ulcers, bullae, and palpable purpura are less frequent

@histology:

Sweet syndrome:

- ✓ A diffuse infiltrate of mature neutrophils is characteristically present in the papillary and upper reticular dermis
- ✓ **Fibrin deposition** or neutrophils within the vessel walls (changes of "primary" leukocytoclastic vasculitis) **are usually absent** and the overlying epidermis is normal

1. Pyoderma gangrenosum :

- ✓ bullous PG shows a subepidermal or intraepidermal bulla with overlying epidermal necrosis and marked upper dermal edema with prominence of neutrophils.
- ✓ **the center:** marked neutrophilic infiltration with abscess formation in the mid and deep dermis extending to the panniculus
- ✓ **peripheral areas:** mixed or predominantly lymphocytic inflammatory infiltrate (include macrophage)

2. Erythema nodosum :

- ✓ Thickened septa with inflammatory cells
- ✓ Neutrophils in early lesions and histiocytes and Miescher granulomas in late-stage lesions

3. Nodular vasculitis:

- ✓ **Extensive necrosis of the adipocytes** in the center of the fat lobule
- ✓ neutrophils in early lesions and epithelioid histiocytes and multinucleated giant cells in fully developed lesions
- ✓ **Vasculitis** of the small veins and venules of the fat lobule.

4. Halogenoderma:

- ✓ Papillomatosis may be observed, sometimes to the level of pseudoepitheliomatous hyperplasia or acanthosis
- ✓ Often, intraepidermal abscesses form with neutrophils, eosinophils, and, at times, necrotic or even acantholytic keratinocytes within them
- ✓ **True vasculitis may be present. Eosinophils may also be evident**

5. Leukemia cutis:

- ✓ may revealed abnormal neutrophil compared with mature neutrophil in sweat syndrome.
- ✓ Leukemic cells often infiltrate between collagen bundles in the reticular dermis. The leukemic cells may also infiltrate along the fibrous septae of the subcutaneous fat.

@LAB:

1. Pyoderma gangrenosum :

- ✓ no laboratory test or investigation that establishes the diagnosis of PG with certainty
- ✓ Presence of various circulating autoantibodies

<p>2. Erythema nodosum : elevated ESR and CRP, and leukocytosis</p> <p>3. Nodular vasculitis: may ESR elevated, need TB/NTM survey</p> <p>4. Halogenoderma:</p> <ul style="list-style-type: none"> ✓ Serum or urine bromide and iodide levels should be measured. ✓ Monoclonal gammopathy has been reported in some patients <p>5. Leukemia cutis: anemia, thrombocytopenia, and neutropenia or leukocytosis, elevated LDH and creatinine</p> <p>@course and systemic presentation:</p> <p>1. Pyoderma gangrenosum :</p> <ul style="list-style-type: none"> ✓ The majority of patients with PG have other systemic diseases (such as arthritis, inflammatory bowel disease, hematological dyscrasias, malignant disease, etc ✓ Untreated, course may last months to years but spontaneous healing can occur <p>2. Erythema nodosum:</p> <ul style="list-style-type: none"> ✓ spontaneous resolution in 6 weeks, depends on etiology ✓ fever, malaise, headache and arthralgia (50%, most in ankle joint) ✓ Tonsillitis/pharyngitis/ URI precede 20-30% ✓ associated with non-Hodgkin lymphoma <p>3. Nodular vasculitis:</p> <ul style="list-style-type: none"> ✓ have a protracted course with recurrent episodes over years ✓ <u>no obvious systemic presentation</u> <p>4. Halogenoderma: Halogenoderma resolves 4-6 weeks after the causative factor is eliminated.</p> <p>5. Leukemia cutis:</p> <ul style="list-style-type: none"> ✓ Leukemia cutis most correlates with AML, may also concurrent with sweet syndrome, especially in those patient with hematologic disease treated with G-CSF 	
<p>7. 藥物治療 :</p>	
<p>Main therapy: [* Methylprednisolone inj 針 40mg/vial (Solu-medrol)] 20 mg IVD QD 【([* Sodium chloride 0.9% inj 500mL/bag] 1 bag [常備])] IVD QD [註 : for drug]</p> <p>For fever control: [Acetaminophen 500mg/tab (Paramol)] 1 tab Q6H PRN PO x3 天. [註 : if fever>38°C or pain]</p> <p>Itching relief: [Hydroxyzine 25mg/cap (Vistaril)] 1 cap HS PO [Levocetirizine 5mg/tab (Xyzal)] 0.5 tab QDPC PO</p> <p>Prophylatic antibiotics: [Tetracycline oph oint 藥膏 1% 5g/tube (Tetracycline)] 1 q.s. QD TOPI x7 天. [註 : biopsy wound] (總量:1tube) [Cephalexin 500mg/cap (Cephalexin)] 1 cap Q12H PO x3 天.</p> <p>Others:</p>	

<p>[Acetylcysteine 600mg/tab (Fluimucil)] 1 tab BIDPC PO [Famotidine 20mg/tab (Famotidine F.C.)] 1 tab BIDPC PO</p>																						
<p>8. 其他治療及預防計劃：</p>																						
<p>1. Skin lesions may become secondarily infected and antimicrobial therapy may be necessary 2. Survey for underlying disease, such as hemoproliferative disease or inflammatory bowel disease. In addition, make the patient aware of extracutaneous presentation, such as central nervous system involvement, hematuria and proteinuria, hepatic serum enzyme elevation and pleural effusions.</p>																						
<p>9. 醫病關係之建立及會談、溝通技巧</p>																						
<p>這個病人比較困難的是病情蒐集，因為病程長且如果是沒有症狀的皮膚病灶有時很難定義它冒出來的時間點。加上患者本身印象含糊要花很多時間推敲他講的是否合理，在這裡比較常善用反問法去反駁病人說的時間點。但是病人的脾氣非常好，因此在接這位病人時可以說是非常順利。</p>																						
<p>10. 此例值得討論的重點以及 specific questions</p>																						
<p>提出問題:</p> <p>1. 這個病人總共有 4 個 episodes，每次用局部和口服 steroid 都可以達到緩解(病人自述要花上 1 個月才能達到原本肌膚狀態)，只是常常緩解大約 1-2 周，又會有新的病灶產生，因此第一個問題是那些治療能幫助病人長期緩解?</p> <table border="1" data-bbox="245 1106 826 1294"> <thead> <tr> <th>Database</th> <th>Keywords</th> <th>paper</th> </tr> </thead> <tbody> <tr> <td>PubMed</td> <td>Recurrent sweet's syndrome and treatment</td> <td>4 results</td> </tr> </tbody> </table> <table border="1" data-bbox="245 1294 1114 1753"> <thead> <tr> <th>Interested paper</th> <th>Year</th> <th>Published</th> </tr> </thead> <tbody> <tr> <td>Sweet's syndrome: a review of current treatment options</td> <td>2002</td> <td>Am J Clin Dermatol</td> </tr> <tr> <td>Treatment of recurrent Sweet's syndrome with coexisting rheumatoid arthritis with the tumor necrosis factor antagonist etanercept.</td> <td>2006</td> <td>Journal of the American Academy of Dermatology</td> </tr> <tr> <td>Refractory Sweet's syndrome successfully treated with rituximab</td> <td>2015</td> <td>JAAD</td> </tr> <tr> <td>Long-term suppression of chronic Sweet's syndrome with colchicine</td> <td>2002</td> <td>Am J Clin Dermatol</td> </tr> </tbody> </table> <p>Conclusion:</p>	Database	Keywords	paper	PubMed	Recurrent sweet's syndrome and treatment	4 results	Interested paper	Year	Published	Sweet's syndrome: a review of current treatment options	2002	Am J Clin Dermatol	Treatment of recurrent Sweet's syndrome with coexisting rheumatoid arthritis with the tumor necrosis factor antagonist etanercept.	2006	Journal of the American Academy of Dermatology	Refractory Sweet's syndrome successfully treated with rituximab	2015	JAAD	Long-term suppression of chronic Sweet's syndrome with colchicine	2002	Am J Clin Dermatol	
Database	Keywords	paper																				
PubMed	Recurrent sweet's syndrome and treatment	4 results																				
Interested paper	Year	Published																				
Sweet's syndrome: a review of current treatment options	2002	Am J Clin Dermatol																				
Treatment of recurrent Sweet's syndrome with coexisting rheumatoid arthritis with the tumor necrosis factor antagonist etanercept.	2006	Journal of the American Academy of Dermatology																				
Refractory Sweet's syndrome successfully treated with rituximab	2015	JAAD																				
Long-term suppression of chronic Sweet's syndrome with colchicine	2002	Am J Clin Dermatol																				



Table 10: First-line systemic agents for Sweet's syndrome

Corticosteroids	
Prednisone	1 mg/kg/day (usually ranging from 30 mg to 60 mg) as a single oral morning dose. Within 4 to 6 weeks, taper dose to 10 mg/day; however, some patients may require 2 to 3 months of treatment or intravenous therapy [10,23,49,250]
Methylprednisolone sodium succinate	Intravenously administered (up to 1000 mg per day) over 1 or more hours, daily for 3 to 5 days. This is followed by a tapering oral dose of corticosteroid or another immunosuppressant agent [70,184,223,240,359-361].
Potassium iodide	Administered orally as 300 mg enteric-coated tablets, 3 times each day (for a daily dose of 900 mg) or as a saturated solution (1 gram/ml of water) of potassium iodide (SSKI, also referred to as Lugol's solution), beginning at a dose of 3 drops 3 times each day (9 drops/day = 450 mg per day) and increasing by 1 drop 3 times per day, typically to a final dose of 21 drops/day (1050 mg) to 30 drops/day (1500 mg) [17,20,23,143,198,361-363,368-374,397]. ²
Colchicine	Administered orally at a dose of 0.5 mg three times each day (for a daily dose of 1.5 mg) [20,30,281,284,329,360,371,373,375-377,410].

Colchicine provided effective long-term relief, which was published at 2002 American journal of clinical dermatology. In this paper although the skin lesion relieved well after systemic corticosteroid, new lesion always recurred after tapering the steroid. Therefore the author gave the patient colchicine 0.6 mg twice daily and the skin lesion got well controlled.

Letter

Treatment of recurrent Sweet's syndrome with coexisting rheumatoid arthritis with the tumor necrosis factor antagonist etanercept

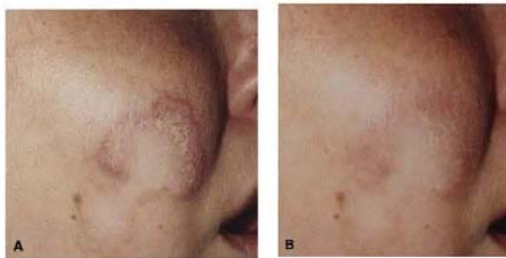
Paul S. Yamauchi, MD, PhD^a, Logan Turner, MD^b, Nicholas J. Lowe, MD^a, Vivian Gindi, MD^a, J. Mark Jackson, MD^b.  

Mechanism like?

TNF- α inhibition has been used successfully as a therapeutic strategy in the treatment of pyoderma gangrenosum, another neutrophilic disorder, with infliximab. By blocking the activity of TNF- α , etanercept effectively decreases the chemotaxis and activation of neutrophils, thus preventing the clinical manifestations of Sweet's syndrome, as demonstrated in these 2 cases.

Case 1- 10-year history of idiopathic Sweet's syndrome

Her previous treatment included systemic corticosteroids, intralesional injections of triamcinolone, and azathioprine, all with intermittent success.



B- after etanercept 6 weeks

Case 2-

After treatment of prednisolone and dapsone, but new skin lesion after discontinue of therapy 2-4 weeks later. Etanercept 25 mg subcutaneous injections twice weekly were initiated. At her 6-month follow-up visit, she reported no recurrence of Sweet's syndrome with etanercept treatment

Refractory Sweet's syndrome successfully treated with rituximab

Lucia Seminario-Vidal, MD, PhD, Cesar Guerrero, MD, and Naveed Sami, MD
Birmingham, Alabama

Case: a white man in his 60s who had a 5-year history of SS refractory to various conventional treatments. RA was not diagnosed but with rheumatoid factor (RF) of 238 U/mL. He had tried prednisolone (1 mg/kg), dapsone (100mg/d), colchicine (0.12 mg/d), mycophenolate mofetil (2.5 g/d), etanercept and adalimumab.

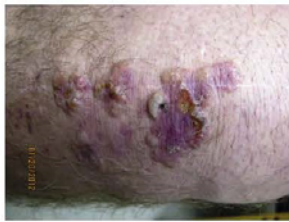

Fig 1. Sweet's syndrome. Scattered erythematous plaques with overlying pustules on the left knee.

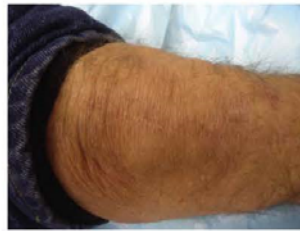


Fig 3. Left knee 22 months after initial rituximab dose.

Hint: Although the pathogenesis of SS is poorly understood, studies have found increased levels of proinflammatory cytokines and chemokines, such as interleukin (IL)-1, IL-8, IL-6, and IL-17; chemokine (C-X-C motif) ligand (CXCL)-1, CXCL-2, CXCL-3, and CXCL-16; TNF- α ; and metalloproteinases. Many of these mediators can be released from B cells and may contribute to disease progression by recruitment and activation of neutrophils

Q2:

有沒有辦法從病人的 symptoms/signs 推估病人是屬於哪個分類?因為此病人第 3 個 episode 有服用 baktar 而且第 4 個 episode 明顯皮膚病灶範圍變大了。

Database	Keywords	Results		
PubMed	sweet's syndrome and clinical feature	46 results		
	drug induced sweet's syndrome and clinical feature	1 results		
	drug induced sweet's syndrome	9 results		
Interested paper		Year	Published	
Sweet's syndrome – a comprehensive review of an acute febrile neutrophilic dermatosis		2007	Orphanet Journal of Rare Diseases	O
Sweet syndrome: long-term follow-up of 138 patients		2015	Clinical and Experimental Dermatology	O
Sweet's syndrome: retrospective study of clinical and histologic features of 44 cases from a tertiary care center		2010	International Journal of Dermatology	X

Results:

Table 2: Clinical features in patients with Sweet's syndrome

Characteristic	Clinical Form			
	Classical ^a	Hematologic malignancy ^a	Solid tumor ^a	Drug-induced ^b
Epidemiology				
Women	80	50	59	71
Prior upper respiratory tract infection	75-90	16	20	21
Recurrence ^c	30	69	41	67
Clinical symptoms				
Fever ^d	80-90	88	79	100
Musculoskeletal involvement	12-56	26	34	21
Ocular involvement	17-72	7	15	21
Lesion location				
Upper extremities	80	89	97	71
Head and neck	50	63	52	43
Trunk and back	30	42	33	50
Lower extremities	Infrequent	49	48	36
Oral mucous membranes	2	12	3	7
Laboratory findings				
Neutrophilia ^e	80	47	60	38
Elevated erythrocyte sedimentation rate ^f	90	100	95	100
Anaemia ^g	Infrequent	82	83	100
Abnormal platelet count ^h	Infrequent	68	50	50
Abnormal renal function ⁱ	11-50	15	7	0

Sweet's syndrome – a comprehensive review of an acute febrile neutrophilic dermatosis

Parameter	Malignancy-associated		P
	Yes (n = 35)	No (n = 103)	
Age, years	59.66	48.38	< 0.001
Sex (M/F), %	65.71/34.19	41.75/58.25	0.02
Fever, %	54.29	60.78	
Location of 55 lesions, %			
Arms	71.43	75.73	
Head and neck	40	26.21	
Trunk	54.29	52.43	
Legs	48.57	54.37	
> 10 lesions (117 valid cases), %	48.39	36.05	
Other neutrophilic dermatoses, %	8.82	6.80	
Pathergy, %	2.86	2.91	
Oral involvement, %	2.86	5.83	
Ocular involvement, %	2.86	2.91	
Recurrent SS (≥ 1 relapse), %	8.57	18.45	
Arthralgia, %	2.86	41.75	< 0.001
Laboratory findings			
ESR > 30 mm/h (51 valid cases), %	87.50	69.77	
Mean ESR, mm/h	60.00	55.05	
Neutrophilia* (119 valid cases), %	25	50.57	0.01
Mean neutrophil count $\times 10^9/L$	5.5	6.9	
Anaemia ^g (119 valid cases), %	87.50	27.59	< 0.001
Mean haemoglobin, g/L	84.3	120.0	< 0.001
Thrombocytopenia ^h (119 cases), %	53.12	4.94	< 0.001
Mean platelet count $\times 10^9/L$	176	301	< 0.01

ESR, erythrocyte sedimentation rate. Definitions: *neutrophil count $> 6 \times 10^9/L$; †haemoglobin < 130 g/L in men and < 120 g/L in women; ‡platelet count $< 150 \times 10^9/L$.

Our patient Hb=124 (which side he is?)

Sweet syndrome: long-term follow-up of 138 patients

Table 3: Medications associated with drug-induced Sweet's syndrome [a-c]

Antibiotics	Minocycline [110-112] Nitrofurantoin [113] Norfloxacin [114] Ofloxacin [115] Quinupristin/dalfopristin [118] Trimethoprim-sulfamethoxazole [11,13]
Antiepileptics	Carbamazepine [17] Diazepam [86]
Antihuman immunodeficiency virus drugs	Abacavir (synthetic carbocyclic nucleoside analogue) [69]
Antihypertensives	Hydralazine [107]
Antineoplastics	Bortezomib [d] [78-79] Imatinib mesylate [e] [108,109,401] Lenalidomide [f] [426]
Antipsychotics	Clozapine [82]
Antithyroid hormone synthesis drugs	Propylthiouracil [117]
Colony stimulating factors	Granulocyte-colony stimulating factor [39,41,89-105,398] Granulocyte-macrophage-colony stimulating factor [105,106] Pegfilgrastim [g] [116]
Contraceptives [83]	Levonorgestrel/ethinyl estradiol (Triphasil) [84] Levonorgestrel-releasing intrauterine system (Mirena) [85]
Diuretics	Furosemide [88]
Nonsteroidal anti-inflammatory agents	Celecoxib [80] Diclofenac [87]
Retinoids	All-trans retinoic acid [70-77,417] 13-cis-retinoic acid [81,404]

Sweet's syndrome – a comprehensive review of an acute febrile neutrophilic dermatosis

Hint:

In patients with drug-induced Sweet's syndrome, neutrophilia is often absent. Our patient had neutrophilia (WBC:20400/ul, Seg(%):74, Band(%):6) and anemia(Hb=12.4). It's hard to know which classification of Sweet syndrome meets with the patient's skin lesion. Judging from anemia and abnormal platelet number I will guess drug or hematologic-induced, but from the aspect of neutrophilia the classical is possible.

Table 1: Diagnostic criteria for classical Sweet's syndrome versus drug-induced Sweet's syndrome

Classical ^a	Drug-induced ^b
(1) Abrupt onset of painful erythematous plaques or nodules	(A) Abrupt onset of painful erythematous plaques or nodules
(2) Histopathologic evidence of a dense neutrophilic infiltrate without evidence of leukocytoclastic vasculitis	(B) Histopathologic evidence of a dense neutrophilic infiltrate without evidence of leukocytoclastic vasculitis
(3) Pyrexia >38°C	(C) Pyrexia >38°C
(4) Association with an underlying hematologic or visceral malignancy, inflammatory disease, or pregnancy, OR preceded by an upper respiratory or gastrointestinal infection or vaccination	(D) Temporal relationship between drug ingestion and clinical presentation, OR temporally-related recurrence after oral challenge
(5) Excellent response to treatment with systemic corticosteroids or potassium iodide	(E) Temporally-related resolution of lesions after drug withdrawal or treatment with systemic corticosteroids
(6) Abnormal laboratory values at presentation (three of four): erythrocyte sedimentation rate >20 mm/hr; positive C-reactive protein; >8,000 leukocytes; >70% neutrophils	

另一篇

CLINICAL AND LABORATORY INVESTIGATIONS

DOI 10.1111/j.1365-2133.2006.07677.x

Sweet's syndrome: a spectrum of unusual clinical presentations and associations

C.Y. Neoh, A.W.H. Tan and S.K. Ng

National Skin Centre, 1 Mandalay Road, Singapore 308205, Singapore

This is a retrospective study of all consecutive cases of SS seen at National Skin Centre, Singapore during 1999-2004. Thirty-seven patients were identified.

Atypical Sweet's syndrome

1. bullous lesions: 以前有研究說到與 Hematologic 有關，但這篇 paper 的結果沒有此相關性

2. SS with hand involvement or neutrophilic dermatoses of the hands

3. the concomitant existence of subcutaneous SS with pyoderma gangrenosum.

Histopathological variants

1. subcutaneous SS:可能與 hematologic 有關	
2. admixture of mature and immature neutrophils: 與 hematologic 有關	
11. 此例之學習心得	
其實光是鑑別診斷我就覺得非常難了，如果一個疾病要依賴 criteria 就表示他非常難懂。Sweet syndrome 就算 biopsy 出來也常有一些不典型的表現，在臨床方面又會與某些 neutrophilic dermatoses 共存，就算得知 underlying disease 是甚麼，對於鑑別診斷也無任何幫助(因為那些鑑別診斷也都會有那些 underlying disease)。雖然是這樣，幸好那些難分難捨的鑑別診斷的治療大多都是 steroid，所以病人都還是可以得到適當的治療，就連生物製劑的方向也大多一致，算是不幸中的大幸，只可惜 sweet syndrome 復發的機率好像不低。	



成功大學醫學院附設醫院教學病歷紀錄表(續：第 頁)

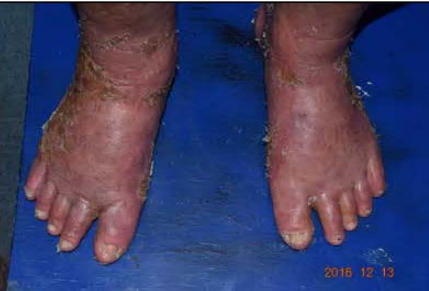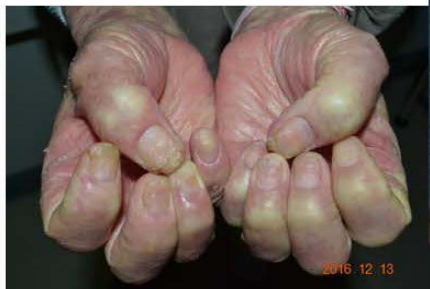()門診 ()住院醫師
 (v)住診 (v)實(見)醫師

指導老師 李玉雲教授 被指導者 _____ 科別 皮膚科 日期 _____

病患基本資料(病歷號：07670xxx)		Student portrait here
姓名：柯 XX	職業：無	
性別：XX	婚姻狀況：已婚	
年齡：XX	籍貫：台灣-福佬人	
教學內容	指導老師修正意見	
主要診斷: Erythroderma, suspect drug eruption 次要診斷: 1. Hyponatremia 2. Hyperkalemia 3. Hypertension 4. Benign prostate hyperplasia		
1. 病史：		
Chief complaint:		
Progressive, itching, generalized erythematous maculopapular skin lesion for about 1 month		
Present illness:		
<p>This 81-year-old man has underlying disease of hypertension under drug control(CO-DIOVAN and furosemide). He also has seborrheic dermatitis over 3 years, 10+ solar keratosis over scalp and extremities, coronary artery disease s/p PCI under clopidogrel usage for 3 years, carotid artery stenosis s/p stent and benign prostatic hyperplasia under silodosin usage and OPD f/u in our urology department. This time he came to our OPD due to progressive, itching , generalized erythematous maculopapular skin lesion for about 1 month.</p> <p>He once being admitted to our ward during 2016/10/25 to 2016/10/29. Skin biopsy on right forearm was done on that admission episode, revealing result was related to drug eruption. The suspected culprit was Ponstan. His condition improved after receiving the medication of Solu-medrol 20 mg QD and antihistamine.</p> <p>After being discharged from our ward, he was in prednisolone usage and OPD follow-up. At that episode, prednisolone was tapered gradually, while progressively generalized erythematous maculopapular eruption recurred in recent 1 month. He denied taking self-bought NSAIDs after discharge, and ever received painkiller injection in outside clinic 2 days ago. Mild chillness was complained, and there was no symptom or sign of upper respiratory infection or urinary tract infection recently.</p> <p>Reviewing his drugs history, he kept taking Clopidogrel, Furosemide, Co-DIOVAN since 7/28. In order to find out the culprit about the suspected</p>		

<p>drug eruption in this episode and to relieve his symptoms, he was admitted to our ward for further evaluation and management.</p>	
<p>Past history:</p>	
<p>(1) Eczema for 3 months (2) 10+ solar keratosis over scalp and extremities (3) Benign prostatic hyperplasia (4) Coronary artery disease s/p PCI (5) Carotid stenosis s/p stent placement (6) Hypertension Drug allergy: ponston TOCC:Travel history(-),Occupation(-),Contact history(-),Cluster(-)</p>	
<p>Social history:</p>	
<p>Smoking(-), drinking(-), betel nut(-)</p>	
<p>Family history:</p>	
<p> </p>	
<p>Current medication:</p>	
<p>Oral clopidogrel, furosemide, Co-DIOVAN, silodosin, prednisolone</p>	
<p>2. 理學檢查 : (Pertinent results)</p>	
<p>Vital Signs: T: 37°C(12/13 17:10); P: 93/min(12/13 17:10) R: 18/min(12/13 17:10); BP: 192/89mmHg(12/13 17:10)</p> <p>【 Consciousness 】 : clear 【 Sclera 】 : not icteric 【 Conjunctiva 】 : pale 【 Oral/throat 】 : not injected, not dry 【 Neck 】 : JVE(-), stiffness(-), LAP (-) 【 Chest 】 : Inspection: symmetric expansion, no subcostal retraction Palpation: no crepitus</p>	

<p>Percussion: resonance Auscultation: normal BS</p> <p>【Heart】 : Palpation: no heave, no thrill Percussion: no increase of dullness Auscultation: RHB, no murmur</p> <p>【Abdomen】 : Inspection: globular Palpation: soft, no organomegaly, pain (-), tenderness (-), rebound (-) Percussion: tympanic, No shifting dullness Auscultation: BS: normoactive</p> <p>【Limbs】 : warm, no edema, cyanosis (-), lateral weakness (-), palmar erythema (-)</p> <p>【Peripheral pulse】 : symmetric and active</p> <p>【Skin】 :pitting edema (++) on bilateral lower legs, petechiae on forearms</p> <p>NE: Bilateral hearing impairment No focal neurologic sign Motor: symmetric, RUL/LUL 4/4, RLL/LLL 4-/4- Sensory: symmetric</p>	
<p>Cutaneous finding: (Include figure)</p>	
<ul style="list-style-type: none"> -Generalized erythematous maculopapular eruption. -Hyperkeratotic plaques on bilateral lower legs and feet. -Fissures over bilateral palms. -No fissure tongue or geographic tongue. -No mucosal involvement. -Dystrophic toe nails and pitting finger nail. -Multiple pea-sized, purpuril, well-demarcated patches scattering over bilateral limbs 	
<div style="display: flex; justify-content: space-around;">   </div>	



3. 實驗室檢驗：(Pertinent lab data)

Microcytic anemia
Hyponatremia
Hyperkalemia
Neutrophilia

常規 (緊急) 生化檢驗報告

檢驗名稱	血液	血液
(單位)	2016-12-13	2016-12-13
	18:51	18:51
ALBUMIN(g/dL)	4.0	
BUN(mg/dL)		32(H)
CREA(mg/dL)		1.33(H)
eGFR		52(L)
AST(U/L)		32
ALT(U/L)		17
NA(mmol/L)		126(L)
K(mmol/L)		5.7(H)
Glucose (random)(mg/dL)		114

一般 (緊急) 血液檢驗報告

檢驗名稱	血液
(單位)	2016-12-13
	19:03
WBC($10^3/\mu\text{L}$)	8.6
RBC($10^6/\mu\text{L}$)	4.01(L)
Hb(g/dL)	9.0(L)
Hct(%)	28.3(L)
MCV(fL)	70.5(L)
MCH(pg)	22.4(L)
MCHC(g/dL)	31.7(L)
RDW(%)	15.9(H)
Plt($10^3/\mu\text{L}$)	463(H)
MPV(fL)	6.7
Blast(%)	0
Pro(%)	0
Myelo(%)	0
Meta(%)	0
Band(%)	0
Seg(%)	84(H)
Eos(%)	0
Baso(%)	0
Mono(%)	6
Lymph(%)	8(L)
Aty-lym(%)	2
NRBC/Count	0
WBCs	

4. 影像檢查：(Pertinent image data)

Nil.

5. 診斷：(需包括(1)主診斷的 criteria(2)分析並且列出重要的檢查項目，以及其結果是否支持此診斷或是缺少哪些重要的檢查)

(1) There is no absolute criteria for the diagnosis of drug eruption and even if the observed histological changes are compatible with a drug-induced eruption. Biopsy may not definitely exclude alternative causes since there is considerable overlap features.

Despite these limitations, we can still approach the diagnosis through the patient's clinical presentation, medication history and drug causality. Also, the skin biopsy might help by recognition of common patterns.

About pathology criteria, there are no absolute histological or immunohistological criteria for the diagnosis of drug-induced maculo-papular exanthems and even if the observed histological changes are

compatible with a drug-induced eruption, biopsy may not definitely exclude alternative causes since there is considerable overlap with features seen in other entities. In mild cases with no severe signs or symptoms and a clear temporal relationship, clinical information and the morphologic pattern of skin lesions are often sufficient for diagnosis. However, in complex and severe cases or when the precise morphology is unclear, histopathological findings may provide some clues and assist in reaching a correct diagnosis.

(2) Medication history:

*Current medication

Clopidogrel since 2016/7/28

Furosemide since 2016/7/28

Co-DIOVAN since 2016/7/28

Silodosin since 2016/09/21

Prednisolone since 9/19

Oral medication history (not taken at present):

alprazolam(10/18~10/24)

Ponstan 250 mg*3 days for waist pain (10/7~10/9)

SUMAKIN complex (Caffine Anhydrous/ Chlorzoxazone/ Acetaminophen/ Thiamine Disulfide) (10/7~10/9)

koscoal(10/7~10/9)

vistaril(9/30~10/24)

loratidine(9/22~9/24)

Chlorpheniramine melete (9/22~9/24)

OROMIN (Vit B13/Vitb2/Pyridoxine B6/Chlorpheniramine melete)(9/19~9/21)

desloratidine(9/12~9/25)

Dexchlorpheniramine Maleate, antihistamine (9/12~9/18)

diazepam(9/9~9/11)

Betahistine mesylate(9/7~9/11)

phemazopyridine hcl(9/3~9/5)

alinamin(8/28~8/30)

meclizine(8/28~8/30)

novamin injection(8/28)

Mequitazine(8/19~9/2)

mehydrolin(8/19~8/25)

Pathological: Patient refused to undergo skin biopsy.

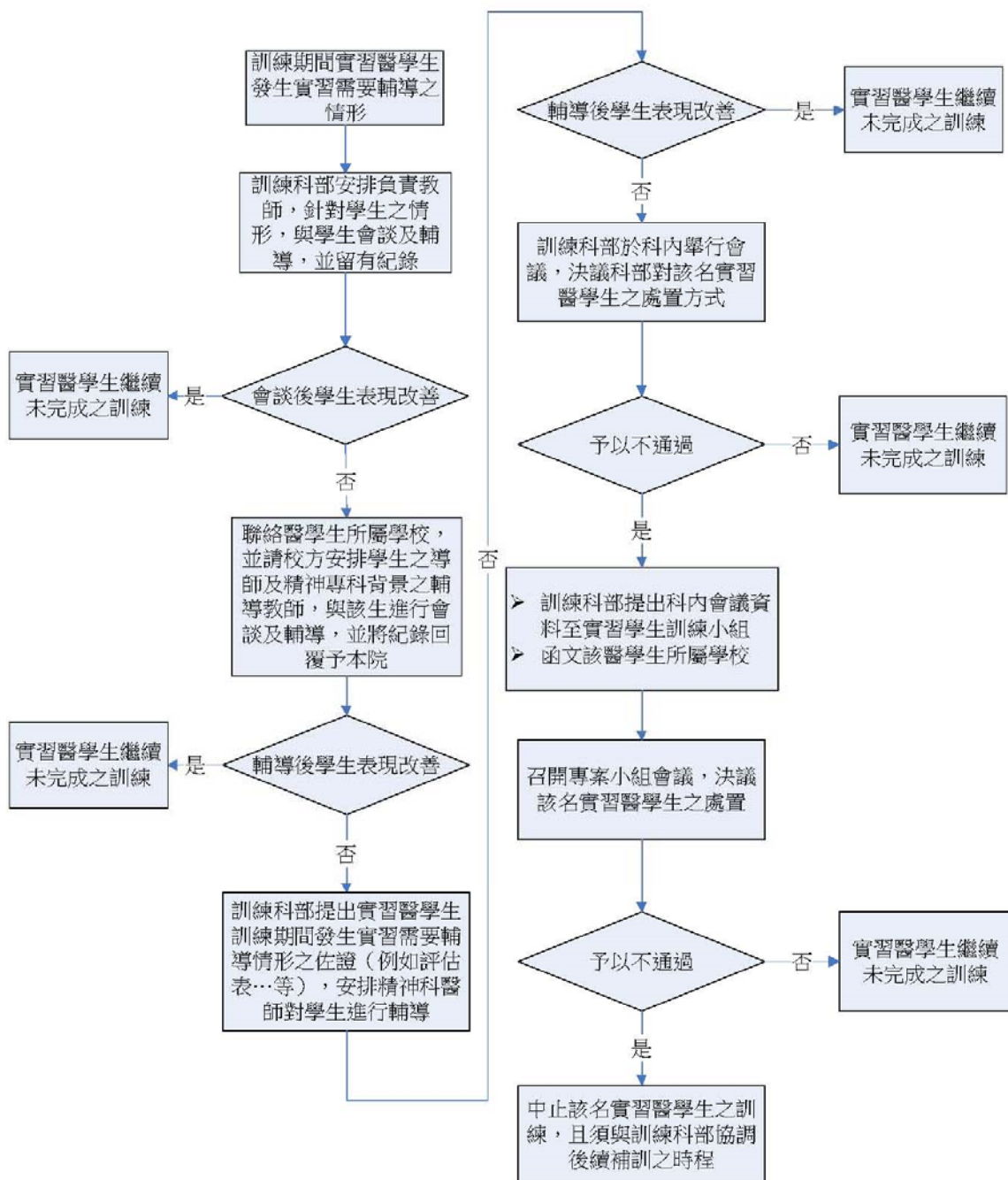
6. 鑑別診斷：(請列出重要的鑑別診斷疾病以及鑑別診斷的重點)

<p>Differential diagnosis about skin rash involving multiple body regions:</p> <ol style="list-style-type: none"> 1. Inflammatory including drug rash and urticaria 2. Infectious 3. Bullous disorders 4. Neoplasm <p>About inflammatory:</p> <ol style="list-style-type: none"> a. There was no significant TOCC history: contact dermatitis might be ruled out. b. No family history about atopic dermatitis c. No target lesions, erythema multiforme might be ruled out. d. No fissure tongue nor geography tongue, psoriasis might be ruled out. e. Skin lesion persisted for over 24 hours, urticarial might be ruled out. f. Clopidogrel and furosemide may cause drug eruption, so we may consider drug eruption in this episode. <p>About infectious: no fever episode</p> <p>About bullous disorders:</p> <ol style="list-style-type: none"> a. Bullous pemphigoid should be considered, but there was no vesicle formation through history. Also, the skin biopsy in September and October showed no evidence about bullous disorder. <p>About neoplasm:</p> <ol style="list-style-type: none"> a. Although mycosis fungoides may be resembled to nonspecific dermatitis, skin biopsy in September and October showed no evidence about neoplasm. <p>Skin biopsy on chest on 2016/09/23: Not suggestive of psoriasis. Drug allergy or eczema may be considered.</p> <p>Skin biopsy on right forearm on 2016/10/25: Compatible with drug eruption.</p> <p>Skin biopsy should be performed on:</p> <ol style="list-style-type: none"> a. Any patient with erythroderma b. Any bullous dermatosis at the edge of the bullae. c. Suspected SJS/TENS 	
<p>7. 藥物治療：</p>	
<p>Solu-medrol 20 mg QD Antihistamine: Allegra 1# BID+ Vistaril 1# HS Topical steroid: Hydrocortisone Topical gentamicin for left forearm erosion.</p>	
<p>8. 其他治療及預防計劃：</p>	
<p>1. Consult CV man for medication adjustment about antihypertensive</p>	

<p>agents and anticoagulants.</p> <p>2. Correct electrolyte imbalance</p>	
<p>9. 醫病關係之建立及會談、溝通技巧</p>	
<p>病患的表達能力可能比較有限，有時因為聽障會答非所問，但他還是會盡可能告訴我現在他感覺如何。作為醫療方，盡可能向他解釋目前的治療方針是甚麼及目前狀況的評估，也可以多問他有沒有聽懂我的意思。如次一來，病患會比較感激有醫療團隊在支持他，進而提高服藥順從性。</p>	
<p>10. 此例值得討論的重點以及 specific questions</p>	
<p>This case may have multiple kinds of drugs allergy. He had been admitted to our ward during 2016/10/25 to 2016/10/29 due to erythroderma. At that time, skin biopsy proved the reason was drug allergy. Ponstan was suspected as the culprit at that episode. This time he was admitted to ward again for the same presence: erythroderma. Preventing the recurrence of drug eruption requires identifying the risk for each individual allergy to different kinds of drugs.</p>	
<p>(1) Question: P: drug eruption I: provocation test C: None O: diagnosis</p> <p>(2) Search for paper: Database: Pubmed Search terms: (drug eruption) AND (safe drug list) Results: 3 articles</p> <p>ORIGINAL ARTICLE Year : 2012 Volume : 78 Issue : 5 Page : 595-598</p> <p>Oral drug provocation test to generate a list of safe drugs: Experience with 100 patients</p> <p>M Ramam, Uttam Kumar, Radhakrishna Bhat, Vinod K Sharma Department of Dermatology and Venereology, All India Institute of Medical Sciences, New Delhi, India</p> <p>BACKGROUND:</p> <p>Following a drug eruption, patients and their doctors need to know which drugs can be safely administered for subsequent illnesses. Currently available laboratory tests are unable to answer this question in a clinically meaningful manner.</p> <p>AIMS:</p>	

<p>To describe our use of oral provocation tests to provide a list of safe drugs to patients.</p> <p>METHODS:</p> <p>We studied the records of 100 patients who underwent oral provocation testing in our department between 2003 and 2009. All patients were admitted to hospital and drugs were administered under supervision, one drug per day. A dermatologist evaluated all symptoms and signs that developed following drug intake.</p> <p>RESULTS:</p> <p>69 women and 31 men underwent provocation testing. There were 96 reactions in 61 patients, of which 44 reactions in 34 patients were judged to be true reactions. All reactions could be controlled, with treatment or spontaneously. A list of safe drugs was provided to the patient along with written instructions to avoid any drug(s) that had produced a reaction.</p> <p>CONCLUSIONS:</p> <p>Oral provocation tests are safe and effective in providing patients with a list of drugs they can take safely. These tests should preferably be undertaken after admitting the patient to hospital.</p>	
<p>11. 此例之學習心得</p>	
<p>第一次看到這位病患時是在門診跟診的時候，當時主治醫師決定收住院。當時我自己認為，根據他使用的藥物，似乎沒有常見會造成過敏的藥物。不過在翻過常用藥品手冊後，才瞭解 Clopidogrel 和 Furosemide 其實也有 report 過 allergy 案例。這次病患需要接受 skin biopsy 以確認是否為 drug allergy 造成，但之前幾個月裡病患已經做過 2 次，故這次拒絕。也希望他這次的病灶能經由調整藥物使用而再也不找上他。同時我也學到以後獨當一面時，只要開藥給病人，一定要衛教說藥要按時吃，如果全身開始發癢、起疹子、脫屑時，就要趕快回來評估是否為藥物疹。如果有發燒、皮膚痛、嘴唇及陰部有紅腫、脫屑時，一定要盡快去急診。</p>	

國立成功大學醫學院附設醫院 實習醫學生輔導作業流程



國立成功大學醫學院附設醫院
實習醫學生學習護照
皮膚部

學生基本資料



(可放您喜歡的照片、圖片或創作)

學生姓名：

聯絡電話：

E-mail：

受訓期間：

_____年_____月_____日至_____年_____月_____日

修訂：_____年_____月_____日

一、反省與實踐（從經驗中學習）

教學中心(102學年度第3次實習醫學生訓練小組會議紀錄 103/03/14)

一、描述令我感到印象最深刻或寶貴的經驗，並記錄這次的經驗為何令我難忘？

二、此經驗對我、病人及整個團隊有何影響？

三、我從這次的經驗中獲得哪些學習及成長？如果對於某些事情我希望能重新來過，下次我會怎麼做？

二、導師回饋

導師簽名：

日期：